Case Report

Langerhans Cell Histiocytosis In Lumbar Spine - A Rare Case Report

Shahidul Islam[1], Ferdous Ara Banu[2], Md. Hasan[3], Fatima Sultana[4], Wayez Mahbub[5], Merina Tanzil[6], Warde Jannat[7], Shammin Mahjabin[8]

Abstract

Background: Langerhans cell histiocytosis (LCH) is an inflammatory myeloid neoplasia caused by mutations in the MAP kinase (MAPK) pathway. It is a rare disorder that can damage tissue or cause lesions in various parts of the body. The disease arises from LCH cells—a type of dendritic white blood cell involved in immune defense.

Objective: To present a rare case of LCH in the lumbar spine for academic discussion.

Methods: This case report was conducted in the Department of Orthopedics and Spine Surgery at Ibn Sina Hospital, Dhanmondi, Dhaka, from October, 2021 to October, 2024. An 11-year-old boy presented with low back pain, bilateral sciatica, weakness of both lower limbs, and inability to walk. Imaging studies, including X-ray, CT scan, and MRI, revealed a solitary osteolytic lesion in the L2 vertebral body, with moderate contrast enhancement on MRI. L2 corpectomy and interbody fusion were performed using a titanium mesh cage with bone grafting. Posterior stabilization was achieved with titanium pedicle screws and rods. Postoperatively, the patient's back pain resolved, and neurological function improved within 2–3 days, allowing ambulation with support. Histopathological analysis confirmed the diagnosis of LCH. No postoperative radiotherapy was administered.

Result: At 10-month follow-up, no local recurrence was observed. Implants and screws were removed. Mesh cage was left in situ. At 3-year follow-up, there was still no recurrence.

Conclusion: In case of lumbar spine LCH, surgery should be considered for neurological deficits or uncertain histological diagnoses. En bloc vertebral resection can alleviate symptoms and prevent local recurrence.

Keywords: Langerhans Cell Histiocytosis; Lumbar Spine; Vertebral Lesion; Histiocytosis; Osteolytic Lesion; Spine Surgery.

1. Professor and Head, Department of Orthopedics and Spine Surgery, Ad-din Women's Medical College, 2, Bara Moghbazar, Dhaka
2. Chief Consultant, Department of Obstetrics and Gynaecology, KB Square Level-5, Barak PRP Medical Centre 736, Sat Masjid Road, Dhaka
3. Associate Professor, Department of Orthopedics and Traumatology, Holy Family Red Crescent Medical College Hospital, 1, Eskatan Garden Road, Dhaka
4. Consultant, Department of Orthopedics and Spine Surgery, Barak PRP Medical Centre, KB Square Level-5, 736, Sat Masjid Road, Dhaka
5. Assistant Professor, Department of Orthopedics and Spine Surgery, Ad-din Women's Medical College, 2, Bara Moghbazar, Dhaka
6. Medical Officer, Department of Orthopedics and Spine Surgery, Barak PRP Medical Centre, KB Square Level-5, 736, Sat Masjid Road, Dhaka
7. Medical Officer, Department of Orthopedics and Spine Surgery, Barak PRP Medical Centre, KB Square Level-5, 736, Sat Masjid Road, Dhaka
8. Medical Officer, Department of Orthopedics and Spine Surgery, Ad-din Women's Medical College, 2, Bara Moghbazar, Dhaka

Correspondence: Dr. Shahidul Islam, Professor and Head, Department of Orthopedics and Spine Surgery, Ad-din Women's Medical College, 2, Bara Moghbazar, Dhaka. Email: drshahid34rmc@gmail.com, Mobile: +8801715111496

Received Date: 01 September, 2025

Accepted Date: 15 September, 2025

Introduction

Langerhans cell histiocytosis (LCH) is a rare proliferative disease originating from dendritic cell family.[1] This disease was named after Paul Langerhans in 1868, after he discovered the epidermal dendritic cells.[2] LCH mainly affects children, mostly in the age range of 1-5 years.[3] The estimated incidence is 1/20000 per year with a male predominance (M:F ratio 2:1).[4] The most common finding of LCH is osseous lesions, with approximately 60% of the patients having one or more lytic osseous lesion, although it can involve multiple systems.[1,5] Skeletal LCH usually affects the skull and femur. In rare cases, it can affect the spine, which eventually results in back pain, radiculopathy, or neurological deficits. Currently, there is no standard treatment protocol for spinal LCH.[1] We report a case of

LCH at L_2 vertebrae, which we treated by L_2 corpectomy. The aim of the study is to present a rare case of Langerhans Cell Histiocytosis (LCH) for academic purposes.

Materials and Methods

This observational study was conducted in the Department of Orthopedics and Spine Surgery in Ibn Sina Hospital, Dhanmondi, Dhaka, over the period of two months from October 2021 to November 2024.

Case Report

An 11-year-old boy, hailing from Thakurgaon, presented to us with complaints of low back pain with bilateral sciatica. The patient developed paraparesis and couldn't walk for the last 15 days. On physical examination, muscle power was grade III. Then he underwent surgery after necessary investigations.

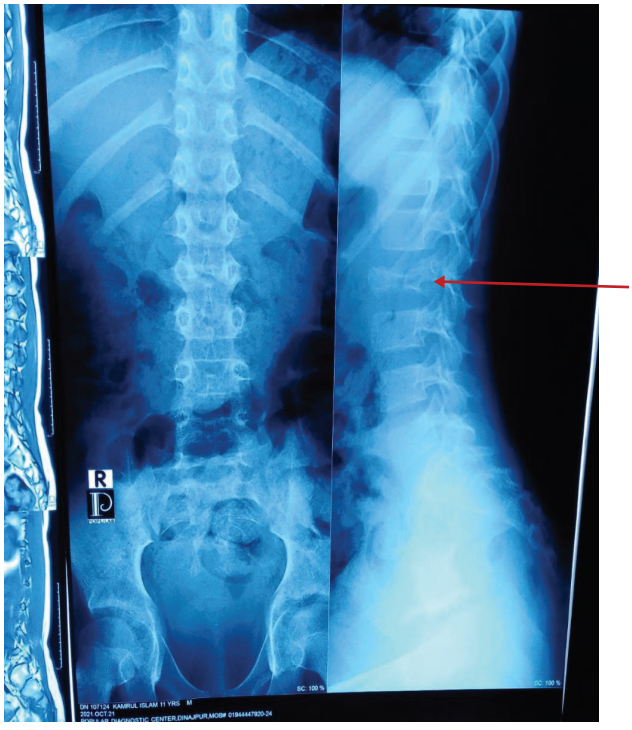

Figure 1: X-Ray of lumbosacral spine revealed vertebra plana of L_2

Vertebra plana is characterized by near-complete collapse and flattening of a vertebral body, with almost total loss of its height. One of the major causes of vertebra plana in children is Langerhans cell histiocytosis.

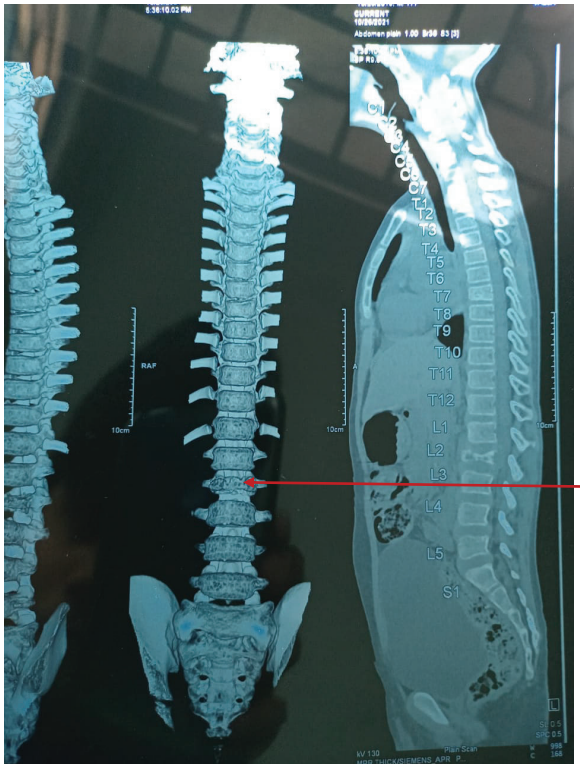

Figure 2: CT scan of whole spine shows solitary osteolytic lesion

Solitary osteolytic lesion affecting L_2 vertebral body, with marked vertebral body destruction/collapse (vertebra plana) and no additional spinal lesions identified.

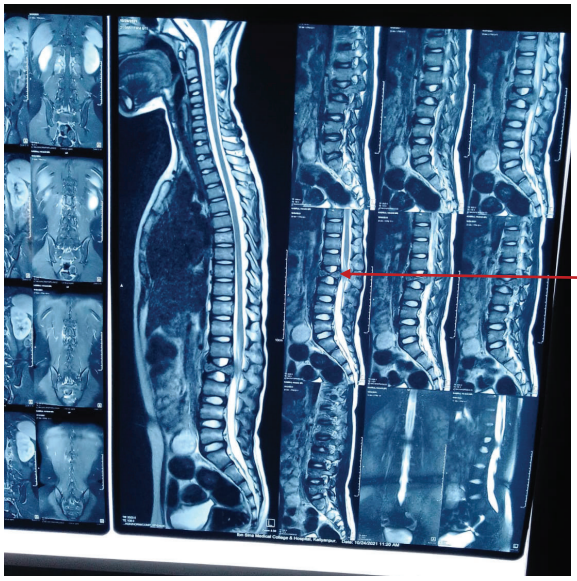

Figure 3: MRI of Spine

MRI revealed vertebra plana of the L2 vertebral body with retropulsion into the spinal canal, causing compression of the thecal sac and cauda equina.

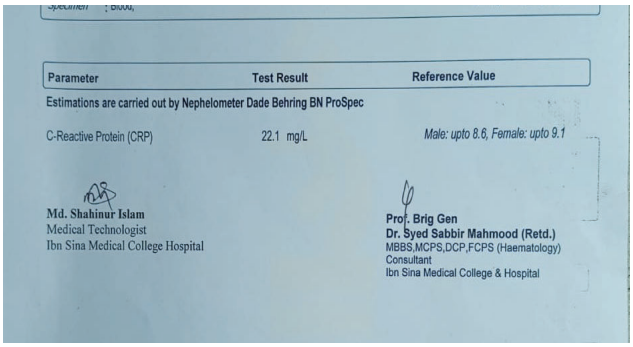

Parameter	Test Result	Reference Value
Estimations are carried out by Nephelometer Dade Behring BN ProSpec		
C-Reactive Protein (CRP)	22.1 mg/L	Male: upto 8.6, Female: upto 9.1

Md. Shahinur Islam
Medical Technologist
Ibn Sina Medical College Hospital

Prof. Brig Gen
Dr. Syed Sabbir Mahmood (Retd.)
MBBS,MCPS,DCP,FCPS (Haematology)
Consultant
Ibn Sina Medical College & Hospital

Figure 4: Patient's CRP was elevated (22.1 mg/dL), indicating inflammation.

The patient underwent L2 corpectomy followed by anterior column reconstruction using a titanium mesh cage packed with autologous bone graft. Posterior stabilization was achieved with titanium pedicle screws and rods.

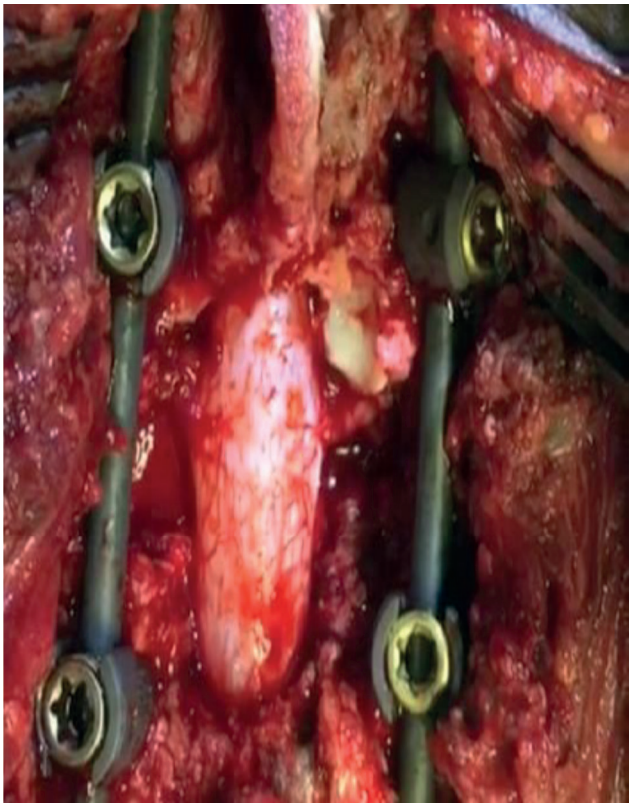

Figure 5: Intraoperative photograph

The photograph is showing posterior spinal instrumentation with titanium pedicle screws and rods following L2 corpectomy. The vertebral defect is reconstructed using a titanium mesh cage filled with bone graft.

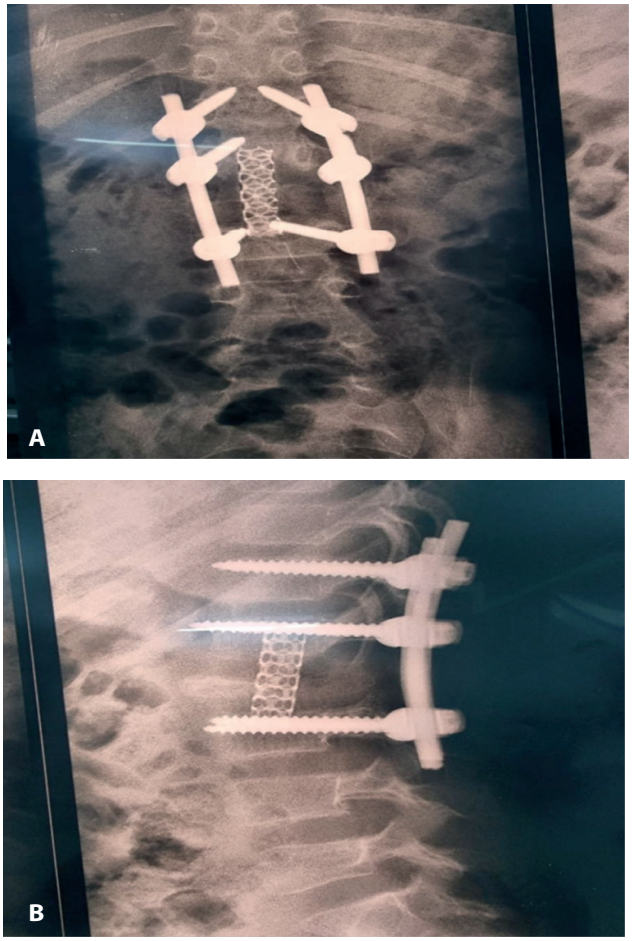

Figure 6: Postoperative anteroposterior (A) and lateral (B) radiographs

It is demonstrating successful reconstruction following L2 corpectomy. Anterior column reconstruction was performed using a titanium mesh cage packed with autologous bone graft, and posterior stabilization was achieved with titanium pedicle screws and rods. The spinal alignment and implant position are satisfactory.



Figure 7: The patient is walking with support

The postoperative course was uneventful. The patient was able to ambulate with support on postoperative day 2. At the 1-year follow-up, the patient had returned to school and was able to ride a bicycle without difficulty.

Discussion

LCH is a rare disease resulting from clonal proliferation of immunophenotypical and functionally immature LCH cells, eosinophils, macrophages, lymphocytes as well, sometimes from multinucleated giant cells.[6] Although the exact etiology is not known yet, it is reported that LCH might be an inflammatory disease and is caused by dysregulation of inflammatory cytokines, eg. interleukin-17.[7] According to a study, more than 50% of LCH cases carry activating mutations in BRAF, and 10% to 28% carry activating mutations of MAP2K1, encoding MEK1.[8]

Langerhans cell histiocytosis, formerly known as histiocytosis X, has three different manifestations: Letterer–Siwe disease, Hand-Schüller-Christian disease, and Eosinophilic Granloma.[9] Among these three clinical subtypes, eosinophilic granuloma involves only bone or lung, having the most favorable outcome with or without local treatment. Almost 80% of LCH lesions in children are of EG type.[10] Hand-Schüller-Christian disease is seen in children over 2-3 years, affects multiple organs, and is often associated with diabetes insipidus, bone gaps, and exophthalmos.[3] Letterer–Siwe disease is clinically rare with poor prognosis.[11] Usually, Letterer–Siwe disease occurs in infants less than 2 years old presenting with fever, skin rash, anemia, hepatosplenomegaly, lymphadenopathy, and bleeding diathesis.[12]

LCH mainly affects children, mostly in the age range of 1-5 years.[3] The estimated incidence is 1/20000 per year with a male predominance (M:F ratio 2:1).[4] This disease can affect any organ of the body, but the skeleton is mostly affected (80%), followed by the skin (33%) and the pituitary (25%). Other organs can also be involved i.e. the liver, spleen, the hematopoietic system and the lungs (15% each), lymph nodes (5–10%), and the central nervous system except for the pituitary (2–4%).[13] In skeletal LCH, the flat bones, the spine, and the long bones are mainly affected.[14] Most frequently involved sites of the skeleton are the skull (26%), vertebrae (7%), ribs (12%), upper and lower jaw (9%), and bones of extremities (11%). In case of spinal LCH, mainly the vertebral bodies are involved, having a predilection for the thoracic spine (54%), followed by the lumbar (35%) and cervical spine (11%).[15] In our patient, L_2 vertebral body was involved. Radiological investigations including plain X-ray, CT scan and MRI revealed vertebra plana and a solitary osteolytic lesion on the L_2 vertebral body, which is compressing the spinal cord.

Radiological investigations identify an osseous lesion but are unable to differentiate between LCH and other osteolytic lesions. A definitive diagnosis is possible by histopathological study of the biopsy.[6] A definitive diagnosis can be made by using CT or C-arm-guided percutaneous needle biopsy in 82-90% of cases. Yet a considerable number of cases cannot be diagnosed accurately in needle biopsy. The reason might be either an inadequate tissue sample obtained in needle biopsy or a lack of typical cellular findings in histological study.[1]

The differential diagnosis of a lytic medullary bone lesion includes non-ossifying fibromas, bone cysts, or osteomyelitis, but also includes malignant tumors, such as metastases, Ewing sarcoma, and lymphoma.[6]

Currently, there are no universally accepted international guidelines available for the diagnosis and treatment of LCH patients. Treatment is usually based on site and extension of the disease.[16] A variety of treatment modalities for spinal LCH have been reported, including conservative management, intralesional steroid injection, radiation therapy, chemotherapy, and curettage with or without reconstructive surgery.[17] Conservative treatment options, such as observation, bracing or immobilization, seem to have a positive impact on the outcome, especially in paediatric patients without neurologic deficit.[18] If there is a solitary bone lesion, neurological involvement, or uncertain histological diagnosis on biopsy, surgical intervention should be considered.[1] Radiation therapy yields a potential risk of developing malignancy in children, but it appears to be safe and effective in adult patients with progressive spinal lesions or neurological impairment.[16] Regarding chemotherapy, prednisolone and vinblastine are preferred by some clinicians.[19] In our case, the patient underwent L_2 corpectomy, where interbody fusion was done by Titanium mesh cage, with bone grafting and stabilization done with titanium pedicle screw & rods through a posterior approach. His low back pain disappeared just after the operation & neurological status was improved after 2/3 days of operation & patient was able to walk with support. A precise diagnosis of LCH was established after a thorough histological study of the removed vertebra. No radiotherapy was given postoperatively.

The prognosis depends on various factors such as the patient, disease, and therapy-related factors. Patients with single-system disease have a better prognosis than

that of multisystem disease.[3] Localized LCH has a prognosis rate of almost 100%, whereas multisystem LCH shows a recurrence rate of ≤50%.[20] Our patient showed a good prognosis during follow-up after 3 years of treatment with no signs of recurrence.

Conclusion

For patients with spinal LCH, neurologic deficit is the main indication for operative treatment to alleviate suffering and prevent further complications. In our patient, low back pain disappeared just after the operation & neurological status was improved after 2/3 days of operation & patient was able to walk with support. LCH was diagnosed after histological study of the specimen. Patient showed satisfactory prognosis with no recurrence after 3 years.

References

1. Chen L, Chen Z, Wang Y. Langerhans cell histiocytosis at L5 vertebra treated with en bloc vertebral resection: a case report. World J Surg Oncol. 2018; 16: 1-6.
2. Langerhans P. Über die Nerven der menschlichen Haut. Arch Pathol Anat Physiol Klin Med. 1868; 44: 325-327.
3. Kouhen F, Benhmiddou N, Afif M, Rais F, Mahdi Y, Khannoussi B, et al. Adult Langerhans cell histiocytosis: a rare etiology of spinal cord compression. Open J Intern Med. 2015; 5(3): 21.
4. Robitaille N, Hume HA. Blood components and fractionated plasma products: preparation, indications and administration. In: Pediatric Hematology. 2006; 32: 691-723.
5. Howarth DM, Gilchrist GS, Mullan BP, Wiseman GA, Edmonson JH, Schomberg PJ. Langerhans cell histiocytosis: diagnosis, natural history, management, and outcome. Cancer. 1999; 85(10): 2278-2290.
6. Dhillon CS, Tantry R, Ega SR, Pophale C, Medagam NR, Chhasatia N. Langerhans cell histiocytosis in the adult lumbar spine: a case report and literature review. J Orthop Case Rep. 2020; 10(9): 28.
7. Badalian-Very G, Vergilio JA, Degar BA, MacConaill LE, Brandner B, Calicchio ML, et al. Recurrent BRAF mutations in Langerhans cell histiocytosis. Blood. 2010; 116(11) :1919-1923.
8. Rollins BJ. Genomic alterations in Langerhans cell histiocytosis. Hematol Oncol Clin North Am. 2015; 29(5): 839-851.
9. Garg S, Mehta S, Dormans JP. Langerhans cell histiocytosis of the spine in children: long-term follow-up. J Bone Joint Surg Am. 2004; 86(8): 1740-1750.
10. Azouz EM, Saigal G, Rodriguez MM, Podda A. Langerhans' cell histiocytosis: pathology, imaging and treatment of skeletal involvement. Pediatr Radiol. 2005; 35: 103-115.
11. Zhou HM, Zeng X, Chen QM. Clinical and pathologic features of Letterer-Siwe disease: a case report and review. West China J Stomatol. 2007; 25(5): 517-519.
12. Aboud MJ, Kadhim MM. Langerhans-cell histiocytosis (LCH): a presentation of two siblings with two different entities. Springerplus. 2015; 4: 351.
13. Haupt R, Minkov M, Astigarraga I, Schäfer E, Nanduri V, Jubran R, et al. Langerhans cell histiocytosis (LCH): guidelines for diagnosis, clinical work-up, and treatment for patients till the age of 18 years. Pediatr Blood Cancer. 2013; 60(2): 175-184.
14. Khung S, Budzik JF, Amzallag-Bellenger E, Lambilliotte A, Soto Ares G, Cotten A, et al. Skeletal involvement in Langerhans cell histiocytosis. Insights Imaging. 2013; 4: 569-579.
15. Kim MC, Sung SH, Cho Y. Langerhans cell histiocytosis of the thoracic spine in an adult. Korean J Spine. 2017; 14(3): 109.
16. Girschikofsky M, Arico M, Castillo D, Chu A, Doberauer C, Fichter J, et al. Management of adult patients with Langerhans cell histiocytosis: recommendations from an expert panel on behalf of Euro-Histio-Net. Orphanet J Rare Dis. 2013; 8: 72.
17. Hassan BW, Moon BJ, Kim YJ, Kim SD, Choi KY, Lee JK. Langerhans cell histiocytosis in the adult lumbar spine: case report. Springerplus. 2016; 5: 1-5.
18. Vielgut I, Liegl-Atzwanger B, Bratschitsch G, Leithner A, Radl R. Langerhans-cell histiocytosis of the cervical spine in an adult patient: case report and review of the literature. J Orthop. 2017; 14(2): 264-267.
19. Lim CS, Cho JH. Spinal epidural involvement in adult Langerhans cell histiocytosis (LCH): a case report. Medicine (Baltimore). 2020; 99(3): e18856.
20. Hashimoto K, Nishimura S, Sakata N, Inoue M, Sawada A, Akagi M. Treatment outcomes of Langerhans cell histiocytosis: a retrospective study. Medicina (Kaunas). 2021; 57(4): 356.