

## Case Report

# Fate of a Primigravida Women with Acute Fatty Liver of Pregnancy (AFLP) Complicated with Multiorgan Dysfunction Syndrome (MODS): An Obstetric Emergency

Tania Noor<sup>1</sup>, Fahmida Mozumder<sup>2</sup>, Bonika Biswas<sup>3</sup>, Laila Noor<sup>4</sup>, Nila Akter Keya<sup>5</sup>

### Abstract

Conditions of causing liver dysfunction, unique to pregnancy may often be difficult to establish the diagnosis. Failing to do so can result in unwanted complexities leading to higher morbidity or mortality both for mother and fetus. Hence, we have a case report of a 23-year-old disoriented, semi-conscious, deeply icteric, primigravid, 35 weeks 5 days twin pregnancy patient. She had complaints of severe abdominal pain, nausea and vomiting along with features of multiorgan dysfunction syndrome (MODS) due to Acute Fatty Liver of Pregnancy. Considering the patients history and clinical evidences, the differential diagnoses was “HELLP syndrome (Hemolysis, Elevated Liver Enzymes, and Low Platelets)” and “Acute Fatty Liver of Pregnancy (AFLP)”. Though the commonly reported HELLP syndrome and uncommon AFLP often mimic each other, clinically, these differ largely in patho-physiological characteristics, quite distinctly. While diagnosis of HELLP syndrome usually based both on clinical and some essential investigations findings, diagnosis of AFLP is based on the clinical presentation itself in adjunct with clear cut compatible laboratory findings using Swansea criteria. Coincidentally, definitive management of both cases is termination of pregnancy. Hence immediate termination of pregnancy along with supportive treatment of liver failure is the main stay management for the optimal maternal and fetal outcome in AFLP, as globally reported.

**Key words:** Primigravida, Acute Fatty Liver of Pregnancy (AFLP), Multiorgan Dysfunction Syndrome (MODS).

### Introduction

Acute fatty liver of pregnancy is a rare complication of pregnancy which may be a life-threatening condition due to micro vesicular infiltration of the liver by fat, leading to liver failure. It usually presents at 36 weeks of gestation, and risk factors include first pregnancy (primigravida), preeclampsia, multiple pregnancies, male fetuses (M:F ratio 3:1) and low BMI (<20 kg/m<sup>2</sup>). <sup>1</sup>

The approximate incidence of AFLP is 1: 7,000 to 1:20,000. <sup>2</sup> Conditions unique to pregnancy that cause liver dysfunction including intrahepatic cholestasis of pregnancy, pre-eclampsia, Hemolysis elevated liver enzymes and low platelet count (HELLP) syndrome and AFLP.

The earliest literature available on AFLP, dates back to 1940, as described by Sheehan as an, “Acute yellow atrophy of the liver”. <sup>3</sup> Following this there have been many reported cases of the disease and its outcome. The hypothesis is, an abnormality in the metabolism of long chain fatty acids in the fetus, lead to an excess of fetal fatty acids entering the maternal circulation, resulting in their deposition in the maternal liver leading to hepatic failure, that can be repeated in future pregnancy. <sup>4</sup>

### The Case:

A 23-year-old female (primigravida) admitted in obstetrics gynae admission ward at mid night with 35 weeks 5 days of twin pregnancy with abdominal pain, nausea and vomiting 10-12times for last 4 days but had no complain of itching. The patient had yellow discoloration of skin and sclera for the last 5 days, as reported.

1. Associate professor (Obstetrics & Gynecology), Ad-din Women's Medical College & Hospital, Dhaka, Bangladesh.
2. Assistant Registrar (Obstetrics & Gynecology), Ad-din Women's Medical College & Hospital, Dhaka, Bangladesh.
3. Associate professor ( Obstetrics & Gynecology), Ad-din Women's Medical College & Hospital, Dhaka, Bangladesh.
4. Professor ( Obstetrics & Gynecology), Ad-din Women's Medical College & Hospital, Dhaka, Bangladesh.
5. Research Officer, Ad-din Research Unit, Ad-din Women's Medical College

**Correspondence:** Dr. Tania Noor, Associate professor (Obstetrics & Gynecology), Ad-din Women's Medical College & Hospital, Dhaka, Bangladesh. Mobile: 01719444643, 01711817480. Email: noortania1983@gmail.com, ark3380@gmail.com

Received Date : 20 October, 2023

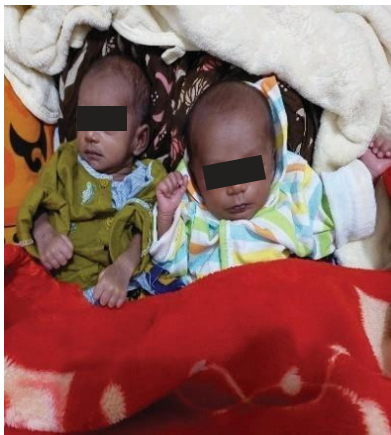Accepted Date : 25 December 2023

### Recent History

The patient was admitted into another nearby hospital 4 days before, as her condition got deteriorated, the patient was brought to our hospital for better management. She was on irregular antenatal checkup and her pregnancy remained uneventful up to 35 weeks.

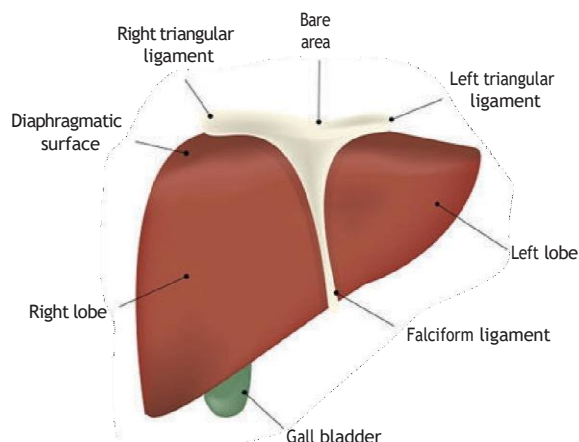


Patient with AFLP

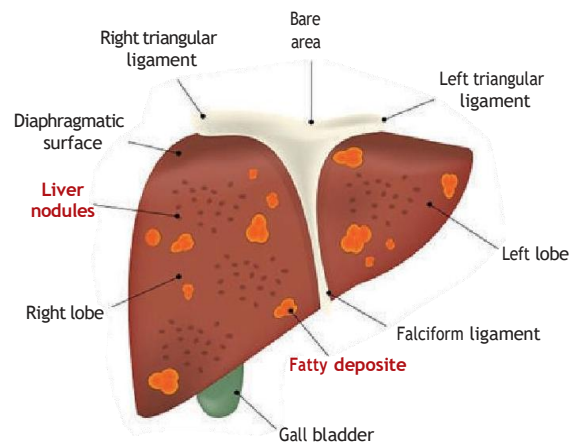


Newborn twins of AFLP patient

### Healthy Liver



### Fatty Liver Disease



### On admission

She had severe abdominal pain, sudden in onset, continuous in nature, did not radiate but relieve a bit using antispasmodic and she did not have any per-vaginal bleeding. Moreover, she had vomiting for 10-12 times, non-projectile, contained food particles, non-bilious and not mixed with blood. Vomiting did not use to relieve her abdominal pain, though, complained of polyuria and polydipsia.

She neither had a history of rise in blood pressure, blurring of vision, nor headache, oliguria or edema. The patient had no history of taking paracetamol, aspirin, sodium valproate or any herbal medicine.

### Physical examination

The patient was ill-looking, semi-conscious, and not oriented to person, place, and time. While her body build was below average, she was mildly anemic, deeply icteric, pulse rate 90 bpm, BP 130/80 mmHg with anti-hypertensive drug. Her body temperature was 98°F and respiratory rate was 18 breaths/min and bedside urine albumin was +1.

On systemic examination, Abdomen was found uniformly enlarged. Symphysio-fundal height was around 36 weeks and revealed two fetuses with breech presentation on longitudinal lie. Abdomen was relaxed and non-tender. On auscultation, two fetal heart sounds were audible with normal range of 110bpm and 122bpm (approx.).

### Examination of nervous system

Revealed signs of hepatic encephalopathy with impaired memory (apraxia), drowsiness, flapping tremor (asterixis), exaggerated tendon reflex (hyperreflexia) and extensor planter reflex (positive Babinski sign.)

### Laboratory Assessment

Investigations of Complete blood count revealed hemoglobin was; 10g/ dl, white blood cell count was; 17,000/cumm, and platelet count was; 1,80,000/cumm. Peripheral smear was negative for hemolysis and serum lactate dehydrogenase (S.LDH) level was 239 mg%. Liver function tests showed aspartate aminotransferase was; 210 U/l, alanine aminotransferase was; 136 U/l, total bilirubin was; 9.3 mg/dl, direct bilirubin was; 7.7 mg/dl, alkaline phosphatase was; 516 U/l, total protein was; 5g/dl, and albumin was; 2.5 g/dl.

### Other biochemical

Revealed blood urea: 40 mg/dl, serum creatinine: 1.8 mg/dl, serum glucose: 60 mg/dl, and serum ammonia: 415 µmol/L. Coagulation profile revealed, prothrombin time of 60 seconds with international normalized ratio (INR) of 3.1, fibrinogen: 62 mg/dl, and fibrin degradation products (FDP): 360 µg/ml. Comb's Test: Negative, S. Amylase: 93 U/L, S. Lipase: 59 U/L, RBS: 3.4 mmol/L. While urine analysis showed mild proteinuria, all serological tests, like; HBsAg, Anti HCV, Anti HAV IgM, Anti HEV IgM and HIV yielded negative findings.

### Ultrasonography (USG)

Ultrasonography (USG) of pregnancy profile revealed two viable fetuses with breech presentation with bright echotexture of liver on USG of hepatobiliary system.

Based on the aforementioned through investigation, the final diagnoses that was established as, Primigravida with

35 weeks 5 days of twin pregnancy with acute fatty liver of pregnancy with hepatic encephalopathy with acute kidney injury (AKI).

### Clinical Management

Though the patient developed coagulopathy, mode of delivery should have been normal vaginal delivery (NVD) but considering the patient's general condition and fetus presentation (both were breech) with unfavorable cervix, decision for urgent Lower segment caesarean section (LSCS) was taken. Coagulopathy was corrected by intravenous Injection Vitamin K (10mg) for 3 days; Fresh Frozen Plasma (FFP) 1unit and PRBC 1 unit was transfused preoperatively.

Counseling was done regarding complications of C-section with possible risk of excessive bleeding, as patient developed coagulopathy. C-section was performed under general anesthesia with prior arrangement of FFP (Fresh Frozen Plasma) and whole blood.

### Surgical Management/ Operation note and subsequent steps taken

During operation bleeding was more than average. There were multiple oozing points in subcutaneous and sub rectal area with multiple rectus muscle haematoma were also present. After proper haemostasis three drain tube kept in situ (intraperitoneal, sub rectus and subcutaneous) to observe further hemorrhage. Intraoperatively, the patient received 1000ml crystalloids, 3 units of fresh frozen plasma (FFP), and 2 unit of whole blood through central venous line. To avoid PPH prophylactically condom catheterization was done.

**Table-1 : Day wise Progress Report of Patient via Parameters of Blood Test**

| Parameters tests      | Day Specific Progress of Treatment based on gradual Laboratory of Blood Parameters |  |   |   |   |
|-----------------------|--|--|---|---|---|
|                       | (1st day of treatment)<br>24.12.22.  | (3rd day of treatment)<br>26.12.22.<br>„0“ OPD | (4th day of treatment)<br>27.12.22<br>1st OPD | (8th day of treatment)<br>31.12.22<br>5th OPD | (15th day of treatment)<br>7.1.23<br>12th OPD |
| S. ALPa               | 516  | 575  | 153   | 120   |   |
| S. ALTb               | 136  | 138  | 48  | 40  |   |
| S. Bilirubinc         | 9.3  | 11.7   | 11.3  | 9   | 3.89  |
| INRd                  | 3.1  | 3.2  | 1.2   | 1   |   |
| WBCe                  | 17,000   | 28,400   | 21,000  | 11,000  | 8,300   |
| S. Uric Acidf         | 7  | 9.1  | 6   | -   |   |
| Total Platelet countg | 1,80,000   | 1,56,000                                       | 1,20,000                                      | 1,40,000                                      | 1,77,000                                      |
| S. Ammoniah           |  | 415  |   |   |   |
| S. Creatininei        | 1.8  | 2.89   | 2.81  | 1.32  | 0.8   |

a-S.ALP- Serum Alkaline phosphatase (ALP)  
b-S.ALT- Serum Aminotransferase, alanine (ALT)  
c-S Bilirubin - Serum Bilirubin:  
d-INR-International normalized ratio  
e-WBC-White blood cell count

f- S. URIC ACID- Serum Uric Acid  
g- Total Platelet count  
h- S.Ammonia- Serum Ammonia  
i- S.Creatinine - Serum Creatinine

Though the patient's vital remained stable, she was shifted to ICU for better and close monitoring and was put on broad-spectrum antibiotic and the newborn was transferred to NICU.

### Therapeutic Modalities Instituted

During puerperal period, symptomatic treatments were going on simultaneously for jaundice, electrolyte imbalance, AKI and DIC. As the patient improved having moderate bleeding in 3 drain tubes, condom catheter was removed on 3rd post-operative day (POD) and all the 3 drain tubes were taken off on the 6th POD, as no further collection of blood in drain tube. The patient required intermittent dialysis for uremia and replacement of blood components to correct coagulopathy.

### Notable Improved Evidence

Her bilirubin and liver enzymes started to decrease and platelets increased from day 10. She made a gradual recovery. Her liver and kidney function returned to normal on day 14. She was managed by 18 units of FFP, 5-unit whole blood and 1 unit apheresis throughout her stay in ICU.

She was shifted to ward from ICU on 12th POD and was under joint consultation with department of internal medicine. On 15th POD, wound dehiscence was observed and regular dressing of wound area was going on with coverage of broad-spectrum antibiotics: Injection Colistin which was the only sensitive antibiotics of her wound C/S. On 21st POD, secondary stitch was given and the patient was discharged home on 22nd POD with healthy twin babies.

### Discussion

AFLP is an uncommon, but serious, condition that causes a pregnant women to develop a fatty liver. It is unpredictable and unpreventable, but requires immediate treatment to avoid life-threatening complications<sup>6</sup>

Pathogenesis is unknown but probably due to deficiency of 3-hydroxyacyl-CoA dehydrogenase (LCHAD) in the fetus. Maternal-fetal fatty acid metabolism is defective which leads to accumulation of unmetabolized medium and long chain fatty acids in maternal blood and hepatocytes, with deleterious effects on maternal hepatocytes<sup>2</sup>. LCHAD deficiency is autosomal recessive and mothers are often found to be heterozygous for the affected mutation<sup>5</sup>

AFLP usually presents after 30 weeks, and often near term (35-36 week) with gradual onset of nausea, anorexia and malaise, severe vomiting, abdominal pain,

jaundice (usually appears within 2 weeks of the onset of symptoms), hypoglycemia, polyuria and polydipsia.<sup>7</sup>

Clinical signs include jaundice, abdominal tenderness, ascites, signs of hepatic encephalopathy, renal impairment, DIC.<sup>8</sup> Mild pre-eclampsia can be present but hypertension and proteinuria are usually mild. Confusion and altered mental status can be present.<sup>9</sup>

The diagnosis of AFLP is usually made clinically, based upon the presentation and compatible laboratory results, that includes:<sup>10</sup>

- Increased white blood cell count
- Raised aminotransferases (5 to 10 times more than the normal range)
- Increased serum bilirubin level
- Elevated prothrombin time
- Increased uric acid level
- Increased ammonia level
- Decrease blood glucose level
- Low fibrinogen

MRI/CT/USG: **Hepatic steatosis**, the liver may appear bright but normal, fat is micro-vesicular

CT: **Decreased attenuation** (fatty infiltration)

Liver biopsy shows fatty change on electron microscope:

Gold standard for diagnosis (*Not always necessary or practical in the presence of coagulopathy*)

According to the **Swansea criteria**<sup>11</sup> for the diagnosis of acute fatty liver of pregnancy, **six or more** of the following findings are required in the absence of another cause

### Clinical signs<sup>10</sup>

- Vomiting
- Abdominal pain
- Polydipsia/polyuria
- Encephalopathy

### Biochemical

#### Hepatic<sup>12</sup>

- Elevated bilirubin > 14 µmol/l
- Elevated transaminases (AST or ALT) > 42 iu/l
- Elevated ammonia > 47 µmol/l

#### Renal<sup>13</sup>

- Creatinine > 150 µmol/l or 2.2 mg/dl
- Elevated urate > 340 µmol/l



### Endocrine

- Hypoglycemia < 4 mmol/l

### Hematological

- Leukocytosis >11x10<sup>9</sup>/L;
- Prothrombin time >14 sec or APPT> 34 sec.<sup>9</sup>

### Radiological

Bright liver on ultrasound scan and, micro vesicular steatosis on liver biopsy, etc<sup>14</sup>

### Treatment

Treatment is immediate delivery of fetus and supportive treatment of other conditions. Other treatment modalities such as plasmapheresis and the use of activated protein C have been practiced in specialized centers.

### Complications include

DIC, Hepatic encephalopathy, Acute Kidney injury, Pancreatitis, Hypoglycemia<sup>14</sup>

### Recurrence

As Recurrences are high up to 10-20%, monitoring of liver function is commonly done as available tool of diagnosis, particularly likely in women who are heterozygous for disorders of fatty acid oxidation.<sup>15</sup>

### Limitations

Limitations of our case report are centered in:

Could not study genetic issues in pregnant women with liver dysfunction and we can't confirm AFL by doing liver biopsy. But this is either due to unavailability of the following tests in Bangladesh and/or huge cost involvement in these genetic issues, like association of MAT liver dysfunction & recessively inherited FAO (fatty acid oxidation) disorders in fetus, mitochondrial trifunctional protein (MTP) catalyzes. We also could not reveal the myths with human defects in MTP complex caused either with isolated LCHAD (long chain 3-hydroxyacyl-CoA dehydrogenase (LCHAD) deficiency or complete MTP deficiency with markedly reduced FAO activity.

And, we could not check if our patient carried fetus with MTP defects being at higher risk of developing liver dysfunction, like: AFLP and HELLP syndrome.

### Conclusion

AFLP is a highly life-threatening hepatic disease occurring during the last trimester of pregnancy and

early puerperium. It is rare, but remain potentially fatal condition mortality & fetal mortality rate 7-18% respectively. The recognition of high-risk factors is helpful for the prevention and management of AFLP. Early diagnosis; prompt delivery; and multidisciplinary supportive care, blood transfusion, and the ICU have resulted in improved maternal mortality, which our findings (case report) yielded. It is also necessary to observe the patient after delivery to ensure better health of the mother and the child.

### References

1. Ademiluyi A, Amakye DO, Jackson N, Betty S. Acute fatty liver of pregnancy. The American Journal of Case Reports. 2021;22:933252-1.
2. Richard H Lee, MD, Nancy Reau, MD, Acute fatty liver of pregnancy, Oct 2023.
3. Sheehan HL. The pathology of acute yellow atrophy and delayed chloroform poisoning. J Obstet Gynaecol Br Emp. 1940;47:49-62.
4. Acute Fatty Liver of Pregnancy - Health Encyclopedia, University of Rochester Medical Center 2024. available from <https://www.urmc.rochester.edu/encyclopedia/content.aspx>.
5. Prasun P, LoPiccolo MK, Ginevic I. Long-Chain Hydroxyacyl-CoA Dehydrogenase Deficiency / Trifunctional Protein Deficiency. 2022
6. Lapinsky SE, Kruczynski K, Slutsky AS. Critical care in the pregnant patient. American journal of respiratory and critical care medicine. 1995;152(2): 427-55.
7. King JJ, Westbrook RH. Pregnancy and liver disease. Evidence-based Gastroenterology and Hepatology 4e. 2019 ; 23:408-24.
8. Ko H, Yoshida EM. Acute fatty liver of pregnancy. Can J Gastroenterol. 2006;20(1):25-30.
9. Werner CJ, Zoller DP, Baskin WN, Eichmann RE. Acute fatty liver of pregnancy associated with maternal and fetal metabolic acidosis. J FamPract. 1988 ;26:198-9.
10. Weerakkody Y, Jones J, Glick Y, et al. Acute fatty liver of pregnancy. Reference article, Radiopaedia.org (Accessed on 12 Nov 2023)
11. Dey M & Reema K. Acute Fatty Liver of Pregnancy. N Am J Med Sci. 2012;4(11):611-2.
12. Lim E, Mouyis M, MacKillop L. Liver diseases in pregnancy. Clin Med (Lond). 2021 ;21(5):e441-e445.

13. Hendrie JD, Blumer MC, Fenton HH, Abrams GA. Two Fatty Liver Conditions Masquerading as Autoimmune Hepatitis. *Case Reports Hepatol*. 2021; 11: 1-5
14. Hadi Y, Kupec J. Fatty Liver in Pregnancy. In: *StatPearls* [Internet]. Treasure Island (FL): StatPearls Publishing; 4th July, 2023
15. Bellig LL. Maternal acute fatty liver of pregnancy and the associated risk for long-chain 3-hydroxyacyl- coenzyme a dehydrogenase (LCHAD) deficiency in infants. *Advances in Neonatal Care*. 2004;4(1): 26-32.
16. Meng Z, Fang W, Meng M, Zhang J, Wang Q, Qie G, Chen M, Wang C. Risk factors for maternal and fetal mortality in acute fatty liver of pregnancy and new predictive models. *Frontiers in Medicine*. 2021; (5); 8-9
17. Pop LG, Suciu ID, Suciu N, Toader OD. Acute fatty liver of pregnancy. *Journal of Interdisciplinary Medicine*. 2020;5(1):23-6.