

## Case Report

# A Lady with Unilateral Painful Orbital Swelling with Possible Euthyroid Graves Ophthalmopathy

Mohammad Moin Shahid<sup>1</sup>

### Abstract

**Background:** Thyroid ophthalmopathy is one of the cardinal features of Graves' disease. But it can also be found in patients with euthyroid, even with hypothyroid status.

**Case:** A twenty-four years old unmarried, non-smoker lady came with complaints of right-sided proptosis for 4 months. The protrusion of her right eye was gradually increasing and there was continuous dull aching pain. There was no history of neck swelling, weakness, palpitation, excessive sweating, weight loss, or tremor. Investigations revealed that she was in euthyroid state but her antibody titer of thyroid stimulating hormone receptor antibody was found beyond the normal range. She was managed conservatively.

**Conclusion:** Euthyroid Graves' ophthalmopathy is usually a self-limiting condition. However, it can be vision-threatening if proper evaluation and early management are not done.

**Keywords:** Thyroid ophthalmopathy, Graves' disease, Euthyroid, Proptosis

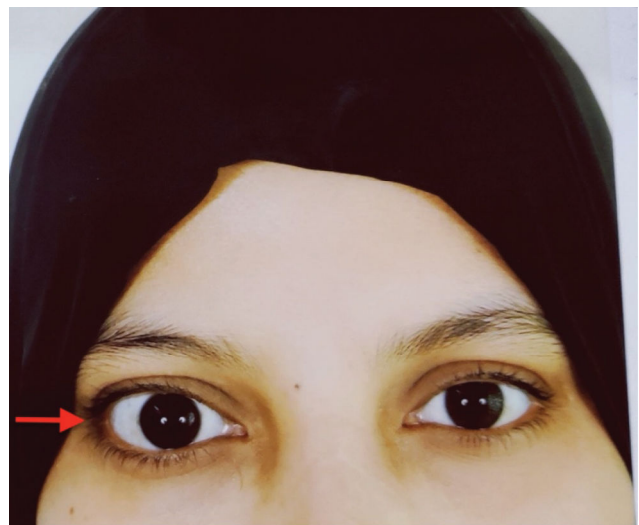### Introduction

Ophthalmopathy is one of the cardinal features of Graves' disease (GD)<sup>1</sup>. It is a condition where thyroid auto-antibodies react against the thyroid gland, extraocular muscles, retro-orbital tissues like orbital fat, and lacrimal glands resulting in orbitopathy – lid lag, lid retraction, chemosis, exophthalmos, extra-ocular muscle palsy, and even blindness<sup>2</sup>. The interesting thing about thyroid-associated ophthalmopathy is that to develop this condition patient does not need to be in a hyperthyroid state - it can develop even in the hypothyroid and euthyroid state<sup>2,3</sup>. Its peak incidence is in the twenties and thirties, but it can occur at any age - although it is uncommon before puberty. It is more common in women than men with a ratio over 5:1<sup>3,4</sup>.

### Case report

A twenty-four-year-old unmarried, non-smoker lady reported to the outpatient department of Ophthalmology (GO) with a painful proptosis of the right eye for four months. Her protrusion of right eye was gradually increasing and there was a continuous

localized dull aching pain in her right eye which aggravated with the movement of the eyeball but did not subside completely after taking rest and analgesics. She had no complaint regarding her left eye. Her previous personal and family history was negative for thyroid disorders. There was no preceding history of defective vision or blackouts transient loss of vision or defective color perception. There was no history of neck swelling, weakness, palpitation, excessive sweating, weight loss or tremor. She denied of taking antithyroid drugs, thyroid surgery or radio-iodine ablation of the thyroid gland.

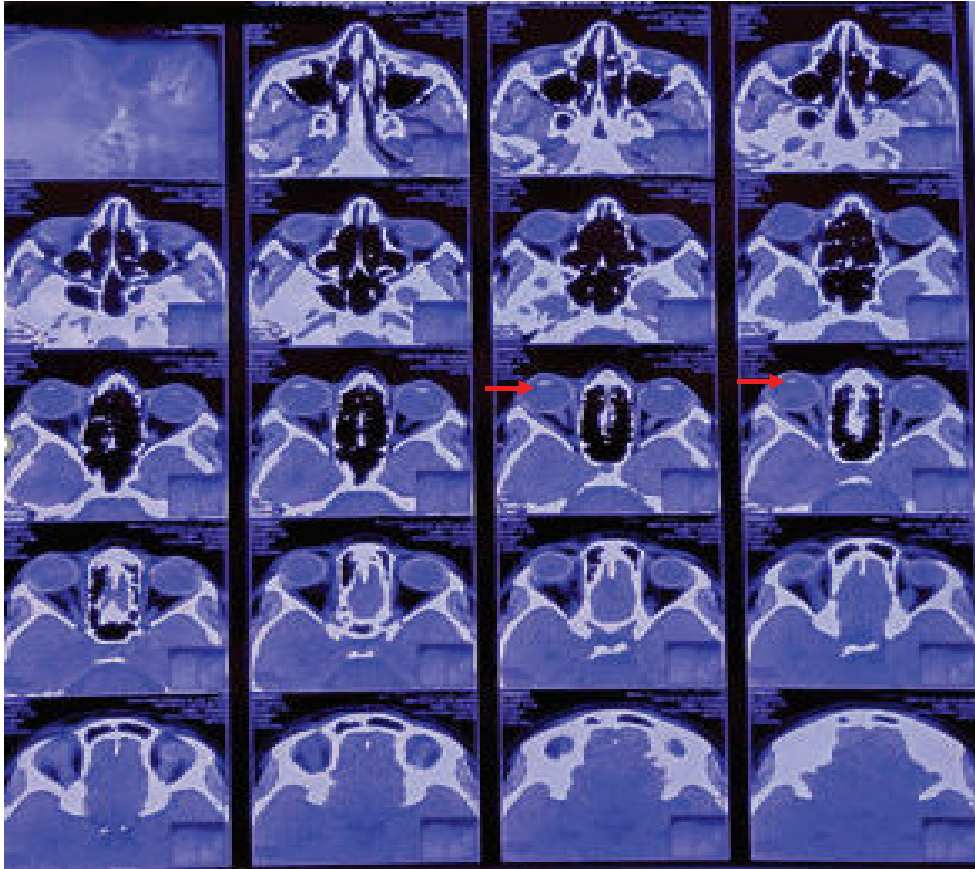


**Figure 1: Right sided unilateral proptosis**

**Correspondence:** Dr. Mohammad Moin Shahid, Associate Professor, Department of Endocrinology, Ad-din Women's Medical College. Phone: 01817028202, E-mail: dr.ms952@gmail.com

**Received Date :** 11 June, 2024

**Accepted Date :** 14 July, 2024



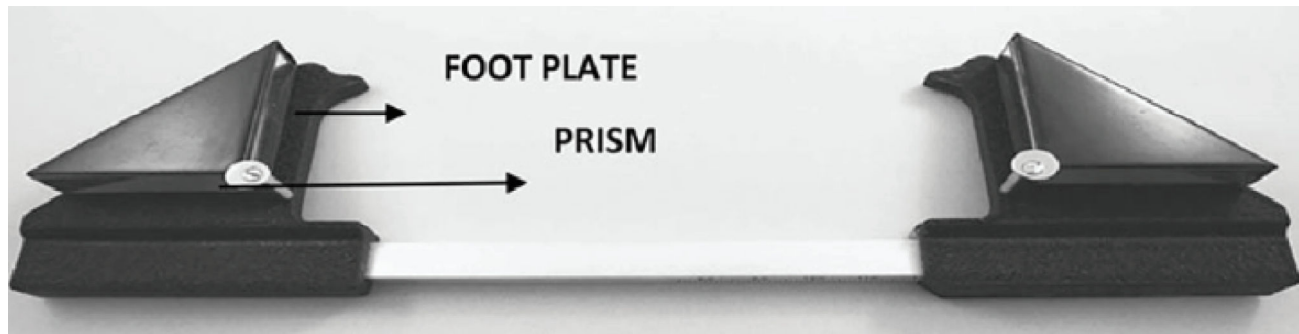
**Figure 2: Axial view**



**Figure 3: Sagittal view**

On ocular examination, her visual acuity was not compromised (6/6 in both eyes), Hirschberg reflex was central in both eyes with unilateral axial proptosis of the right eye of 3mm measured by Hertel Exophthalmometer (Figure 4). Dalrymple sign (lid retraction) (Figure 1), Von Graefes' sign (lid lag on downgaze), Mobius' sign (convergence deficiency), and Kochers' sign (staring look and frightening appearance of eyes) were positive in her right eye. Ocular motility was full in all cardinal positions of gazes and there were no complaints of diplopia. The patient received 5/7 in Clinical Activity Score (CAS) due to her orbital pain, gaze-evoked ocular pain, eyelid edema, conjunctival congestion, redness, and inflammation of the lacrimal caruncle in her right eye. But her left eye's CAS was 0/7. Her intraocular pressure was normal in both eyes. MRI of orbits revealed unilateral right-sided exophthalmos predominantly caused by the thickening of the medial rectus muscle (Figure 2,3).

She had no thyroid gland swelling and her pulse rate was 76 beats/minute. Her complete blood count (CBC) revealed no abnormality. Thyroid function tests showed



**Figure 4: Hertel Exophthalmometer<sup>11</sup>**

she was in euthyroid state (F.T3 – 3.22 pg/ml (reference value: 1.45 – 3.48 pg/ml), F.T4 – 0.963 ng/dl (reference value: 0.7 – 2 ng/dl), TSH – 1.08  $\mu$ U/ml (reference value: 0.350 – 5.50  $\mu$ U/ml). But her Thyroid stimulating hormone receptor antibody (TRab) level was in favor of GD (TRab – 2.33 Units/L; reference value: negative  $\leq$  1 Units/L, borderline > 1 – 1.5 Units/L, positive > 1.5 Units/L). Since TRab is highly specific for GD, she was diagnosed as a case of Euthyroid Graves' Ophthalmopathy.

She was prescribed lubricants carboxy-methylcellulose 1% eye drop day time and ointment at night along with topical NSAIDs with a plan to start systemic corticosteroid (Prednisolone) if her condition does not improve. She came for a follow-up visit after one month. Her proptosis regressed significantly and pain disappeared. During her follow-up visit after 3 months, her eye swelling was found completely disappeared and she has been without any medication since then.

### Discussion

Thyroid-associated ophthalmopathy is an organ-specific autoimmune process resulting from a complex interplay of genetic (e.g., HLA) and environmental factors. Patient's susceptibility may be determined by genetic factors but its course is influenced by the environment<sup>5</sup>. The development of GO is usually a slow process which takes weeks<sup>3</sup>.

In patients with GD, thyroid autoantibodies (circulating T cells directed against certain antigens on thyroid follicular cells) detect the same antigenic epitopes that are shared by preadipocytes and fibroblasts tissues in the orbital space and extraocular muscles<sup>6,7</sup>. Adhesion molecules like ICAM-1, VCAM-1, and CD4 help in the recruitment of T cells and the activation of lymphocytes. Facilitating interactions between immune-competent

cells, connective tissue cells, and extracellular matrix components, adhesion molecules take active participation in various inflammatory processes, many of which result in amplification of the cellular immune process in active GO<sup>5</sup>. Increased level of thyroid autoantibodies (e.g. TRab) stimulates orbital tissue differentiation either directly or through cytokines and chemokines (e.g. oxygen free radicals). Inflamed cells in orbit release cytokines, chemokines, and various growth factors (e.g. fibroblast growth factor) which act upon orbital preadipocytes stimulating adipogenesis, fibroblast proliferation, glycosaminoglycan synthesis, and the expression of immunomodulatory molecules<sup>5,6,7,8</sup>.

In a similar study, more than 90% of the GO cases are associated with hyperthyroidism. Patients with euthyroid Graves' disease typically have high levels of both stimulating and blocking TSH receptor antibodies (TRAb). Though these antibodies cancel each other's effect they are both capable of eliciting an immune response in orbital tissue resulting in the development of ophthalmopathy<sup>6</sup>.

Euthyroid GO is a self-limiting condition that may last from months to years. It usually consists of two phases – an acute phase followed by a resolution phase. Low titer of TRab is associated with a milder form of ophthalmopathy and early recovery<sup>9</sup>. Possibly this is why the reported case recovered so early – without any complication. Thyroid-associated ophthalmopathy in the euthyroid state is not a common phenomenon<sup>4,10</sup>. So, there is always a very good chance of being misdiagnosed. If properly managed, then significant recovery is very common reducing the risk of developing scar tissue. Otherwise, it may warrant surgical decompression<sup>4</sup>.

## Conclusion

Euthyroid GO is a self-limiting condition yet it can be vision threatening. Proper evaluation and early management must not be neglected in this regard.

## References

1. Jang SY, Lee SY, Lee EJ, Yoon JS. Clinical features of thyroid-associated ophthalmopathy in clinically euthyroid Korean patients. *Eye*. 2012 Sep;26(9):1263-1269.
2. Gardner D, Shoback D. Greenspans Basic and Clinical Endocrinology, Ninth Edition. 9th ed. 2004. 198–201 p.
3. Rabhani SM, Rashid MA, Akhter R, Hossain M. Atypical Presentation of Thyroid Ophthalmopathy A Case Report. *Medicine Today*. 2013 Aug 4;25(1):49-51.
4. Wawhal M, Mogal V, Patil P, Ahire P, Yadav S. Euthyroid ophthalmopathy: A rare case report and a brief review of literature. *Int J Sci Res*. 2015;4:529-532.
5. Heufelder AE, Joba W. Thyroid-associated eye disease. *Strabismus*. 2000 Jan 1;8(2):101-111.
6. Bahn RS. Pathophysiology of Graves' ophthalmopathy: the cycle of disease. *The Journal of Clinical Endocrinology & Metabolism*. 2003 May 1;88(5):1939-1946.
7. Garrity JA, Bahn RS. Pathogenesis of graves ophthalmopathy: implications for prediction, prevention, and treatment. *American journal of ophthalmology*. 2006 Jul 1;142(1):147-153.
8. Shen J, Li Z, Li W, Ge Y, Xie M, Lv M, Fan Y, Chen Z, Zhao D, Han Y. Th1, Th2, and Th17 cytokine involvement in thyroid associated ophthalmopathy. *Disease markers*. 2015;2015(1):609593.
9. Eckstein AK, Plicht M, Lax H, Neuhäuser M, Mann K, Lederbogen S, Heckmann C, Esser J, Morgenthaler NG. Thyrotropin receptor autoantibodies are independent risk factors for Graves' ophthalmopathy and help to predict severity and outcome of the disease. *The Journal of Clinical Endocrinology & Metabolism*. 2006 Sep 1;91(9):3464-3470.
10. Mourits MP, Koornneef L, Wiersinga WM, Prummel MF, Berghout A, Van Der Gaag R. Clinical criteria for the assessment of disease activity in Graves' ophthalmopathy: a novel approach. *British Journal of Ophthalmology*. 1989 Aug 1;73(8):639-644.
11. Jamal RF, Azariah E, Pandyan D, Chinnaswami R. Validation of Modified Hertel Exophthalmometer. *Craniofacial Trauma & Reconstruction*. 2021 Sep;14(3):174-182.