


## Short Communication

# Rationale to achieve Critical View of Safety in Laparoscopic Cholecystectomy

Prof. Dr. Sardar Md. Rezaul Islam

### Introduction

Bile duct injury (BDI) is the most serious iatrogenic complication in Laparoscopic Cholecystectomy (LC). The incidence of major BDI is 0.1 to 0.5%. The most common cause of serious BDI is misidentification. A method of identification of cystic structures was first introduced by Steven Strasburg in USA in 1992. Later he named it Critical View of safety (CVS) in 1995. Three criteria are needed to achieve CVS. 1. Calotte's triangle was cleared of fat and fibrous tissue, 2. Lower third of the gall bladder (GB) is dissected off the cystic plate. 3. Two and only two structures are seen entering the GB which are cystic duct and cystic artery. Some surgeons have adopted this CVS method of dissection. Others use classical infundibular (IN) method or both. We studied the efficacy and safety of CVS technique as sole method of dissection in laparoscopic cholecystectomy.

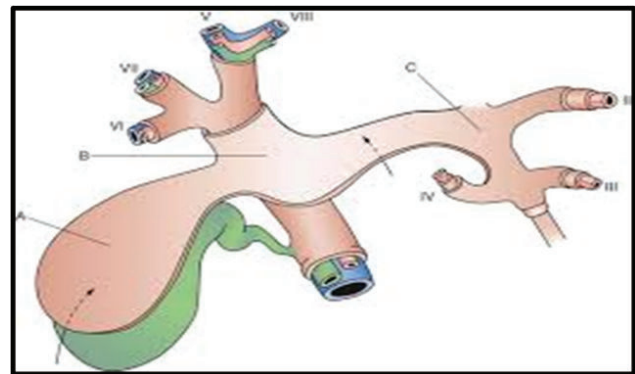


**Fig-1:** Professor Steven Strasburg

**Correspondence:** Prof. Dr. Md. Sardar Rezaul Islam, Professor and Head, Department of Surgery, Ad-din Women's Medical College, Dhaka

**Received Date :** 02 April, 2023

**Accepted Date :** 05 May, 2023



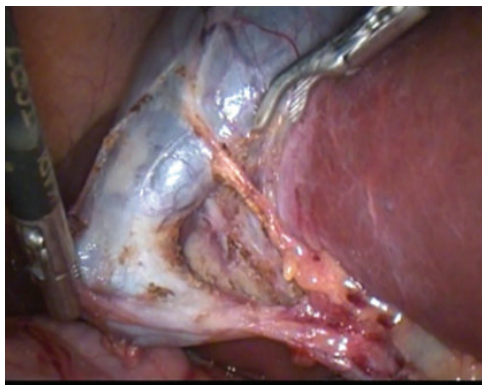
**Fig-2:** Hilar Plate system of liver

### Methods

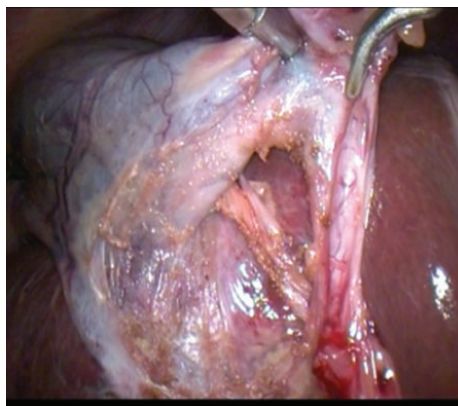
1647 cases of LC were done between January 2012 and January 2022 in two hospitals. All were operated by CVS dissection technique and none by infundibular technique. All operations were carried out by a single surgeon. Data were collected in a retrospective manner. Cases included acute cholecystitis, mucocele, empyema, chronic cholecystitis and simple cholelithiasis. Conventional 4 ports were used. In the CVS technique, complete incision of the serosa is performed both in the medial and lateral aspect of the infundibulum and extended upwards almost to the fundus. Dissection of Calot's artery (which connects the cystic artery to the cystic duct) lateral to the anterior branch of cystic artery permits access to the critical safety triangle. The critical safety triangle is defined as a triangle between the gallbladder wall on the right, the cystic duct inferiorly, and the cystic artery on the left. The entire fatty dissection of this triangle and mobilization of the infundibulum, both anteriorly and posteriorly, permits visualization of the liver surface through the triangle, well above Ruviers' sulcus. The cystic artery and the cystic duct are clipped separately and divided. Afterwards retrograde dissection of the gallbladder completes the operation.

## Results

Average operating time was 42 minutes and range being 13 to 80 minutes. All 3 criteria of CVS were achieved in 1515 (92%) cases out of 1647 cases. Two criteria were achieved in remaining 132 cases. There was no postoperative death in our series. Our rate of conversion was 4.3%. There were two incidence of post operative bile leak, which required drainage and stenting of the CBD (0.12%).



**Fig-3:** Anterior view of CVS



**Fig-4:** Posterior view of CVS

## Discussion

Surgeons have long strived to make LC the safest and complication free procedure. This effort has been made successful to some extent by the introduction and application of CVS.<sup>(1,2)</sup> In our study the operative time is significantly reduced for patients with CVS technique, which is 42 minutes. Vettoretto et al. and Viswanathan V also found significant reduction in operating time (51.5 min), which is comparable to our study.<sup>3,4</sup>

Another important aspect as pointed out by Lam T and Manatakis DK in separate studies is that there is

negligible difference in achieving adequate CVS scores with operator experience (consultant vs. trainees) without adding significant operative time in the hands of trainees. Thus advocating this technique for teaching is largely safe regardless of surgeons experience.<sup>5,6</sup> Although CVs technique may have a little more chance of bleeding as involves dissection of the lower third of the GB while cystic artery supply is still intact.

There was no mortality in our series. Morbidity including minor leaks were only 0.12%. But there was no incidence of major bile duct injury requiring bile duct reconstruction. This finding is superior to many published series, where rate of major BDI in LC was 0.1% to 0.5%.<sup>3,10,11,12</sup>

Currently, the CVS technique is accepted as a Gold Standard for reduction of morbidity and mortality associated with LC by the European Association of Endoscopic Surgery (EAES).<sup>7,8,9</sup> There are no randomized controlled trials published up-to-date to give us level-1 evidence that CVS prevents bile duct injuries.<sup>1,2</sup> However, if we look at the large case series<sup>1,2</sup> published so far, we believe that major BDI can be prevented by strictly adhering to all the three criteria of CVS. The reason is, it helps give reliable exposure to identify important structures of calot's triangle.

## Conclusion

Although the "critical view of safety" requires more dissection as compared to infundibular technique, but once learnt and mastered, it is faster and safer identification technique during laparoscopic cholecystectomy. To prove that CVS dissection method prevents bile duct injury required randomized trial involving a large number of sample. Low rate of complication of this technique probably makes the surgeon feel more secure both with inflamed and uninfamed anatomy. Excellent outcome of our study forecasts that CVS method is the gold standard technique in the dissection of the gallbladder in LC. A further dissemination of the technique is necessary to improve safety in LC.

## References

1. Avgerinos C, Kelgiorgi D, Touloumis Z, Baltatzi L, Derveniz C. One thousand laparoscopic cholecystectomies in a single surgical unit using the "critical view of safety" technique. *J Gastrointest Surg.* 2009;13(3):498–503. doi:10.1007/s11605-008-0748-8.

2. Yegiyants S, Collins J.C. Operative strategy can reduce the incidence of major bile duct injury in laparoscopic cholecystectomy. *Am Surg.* 2008; 74:985–987.
3. Vettoretto N, Saronni C, Harbi A, Balestra L, Taglietti L, Giovanetti M. Critical view of safety during laparoscopic cholecystectomy. *J Soc Laparoendosc Surg.* 2011;15(3):322. doi:10.4293/108680811 X130 71 80407474.
4. Viswanathan V, Garg HP. Critical view of safety technique during laparoscopic cholecystectomy in prevention of biliary injuries. *Int J Int Med Res.* 2016;3(4):35–40.
5. Lam T, Usatoff V, Chan ST. Are we getting the critical view? A prospective study of photographic documentation during laparoscopic cholecystectomy. *HPB.* 2014;16(9):859–863. Yegiyants S, Collins JC. Operative strategy can reduce the incidence of major bile duct injury in laparoscopic cholecystectomy. *Am Surg.* 2008;74(10):985:987. doi:10.1111/hpb.12243.
6. Manatakis DK, Vitalis A, Agalianos C, Terzis I, Kyriazanos ID, Davides D. Teaching and learning the critical view of safety technique in laparoscopic cholecystectomy. *HPB.* 2016;18:e664–e665. doi:10.1016/j.hpb.2016.01.007.
7. Eikermann M, Siegel R, Broeders I, Dziri C, Fingerhut A, Gutt C, et al. Prevention and treatment of bile duct injuries during laparoscopic cholecystectomy: the clinical practice guidelines of the European Association for Endoscopic Surgery (EAES) *Surg Endosc.* 2012;26(11):3003–3039. doi:10.1007/s00464-012-2511-1.
8. Kaya B, Fersahoglu MM, Kilic F, Onur E, Memisoglu K. Importance of critical view of safety in laparoscopic cholecystectomy: a survey of 120 serial patients, with no incidence of complications. *Ann Hepatobiliary Pancreatic Surg.* 2017;21(1):17– doi:10.14701/ahbps.2017.21.1.17.
9. Almutairi AF, Hussain YA. Triangle of safety technique: A new approach to laparoscopic cholecystectomy. *HPB Surg.* 2009;2009
10. Bile duct injury during laparoscopic cholecystectomy: results of an Italian national survey on 56 591 cholecystectomies: *Arch Surg,* 140 (2005), pp. 986-992
11. Iatrogenic bile duct injury: a population-based study of 152 776 cholecystectomies in the Swedish Inpatient Registry: *Arch Surg,* 141 (2006), pp. 1207-1213
12. Bile duct injuries after laparoscopic cholecystectomy: 11-year experience in a tertiary center *Biosci Trends,* 19 (2016), pp. 197-201.