

Original Article

Primary Pterygium Excision with Amniotic Membrane Grafting among Rural Eye Patients in Bangladesh

*MD Abdul Matin¹, Mahbubur Rahman Shahin², Tasnia Nawreen³, Mubashera Sara Khan⁴

Abstract:

Objective: Since treatment of pterygium by topical and systemic medications is not effective, surgical treatment remains the only way to resolve the problem. This study was therefore aimed to evaluate the outcome of primary pterygium excision with amniotic membrane graft among patient with eye diseases in rural Bangladesh.

Methodology: This study was conducted at the Pangsha Eye Hospital of District Rajbari among a total 280 pre-selected eye patients having primary pterygium over the period of 7 years (January 2012-June 2019). Surgical excision was performed with transplantation of preserved amniotic membrane on to the bare sclera. Every patient was followed up for at least next 6 months.

Results: The results were evaluated in terms of recurrent pterygium growth and related complications. Of total 280 patients, pterygium was excision both of 138 (49.29%) being male and 142(50.71%) being female with mean ages of 43.36 ± 10.88 . The pterygium extended on to the corneas for 4.76 ± 1.4 mm (range 3 to 8) mm. Only 11(4%) eyes demonstrated recurrent pterygium. Seven of them were male and 4 were female which was managed by second grafting leading to complete resolution. Of various complications, mild hematoma was observed in 3 cases, and, in 2 cases ~~were~~ had mild sclera dryness in bare scleral area after pterygium excision which were managed by topical steroid and artificial tear.

Conclusion: Findings of this study yielded that primary pterygium excision with amniotic membrane transplantation is remains a safe and effective surgical technique with minimum recurrence rate.

Keywords: Cornea, Pterygium, Amniotic membrane, Conjunctival Autograft

Introduction:

Pterygium is a wing-shaped, fibro vascular growth of the bulbar conjunctiva that crosses the limbs and extends over peripheral cornea. And may cover central parts of the cornea which causes severely visual impairment.¹ It is a common external eye condition, affecting different populations especially in tropical and subtropical regions with a reported prevalence of 2% to 7% worldwide.²

This invasion of the corneal surface can lead to significant visual impairments, irritation of the ocular surface, irregular astigmatism, obstruction of the visual axis and loss of corneal transparency.³ The incidence and

prevalence of this condition vary among different populations and are influenced by a variety of factors including age, sex, and geographical location.³

Worldwide prevalence of pterygium was found to be 10.2%.³ With prevalence rates ranging from 2.8% to in a study⁴ and 33 % in another study.⁵

The prevalence of pterygium in men was also higher than that in women, with rates of 14.5% and 13.6% respectively. Pterygium was more prevalent with increasing age.³ Populations living in geographic latitude ranging from 20-30 also had a higher prevalence of pterygium compared with any other area.³

The nasal limbs are the most common site for pterygium formation. This predilection has been attributed to the focusing of light passing through the anterior chamber at the nasal limbs, causing damage to the limbal stem cell and oxidative stress.^{6,7}

Many population-based studies have also revealed an association between pterygium formation and outdoor occupation and activities, most likely a result of exposure to ultraviolet (UV) radiation, the pathogenesis of which has been described.^{8,9}

1. Professor and Head, Dept. of Ophthalmology, Ad-din Women's Medical College, Dhaka
2. Assistant Professor, Dept. of Ophthalmology, President Abdul Hamid Medical College, Kishoreganj.
3. Medical Officer, Dept. of Ophthalmology, Dhaka Medical College, Bangladesh.
4. Medical Officer, Dept. of Ophthalmology, Ad-din Women's Medical College, Dhaka

Correspondence: Dr. Md. Abdul Matin, Professor and, Head, Dept. of Ophthalmology, Ad-din Women's Medical College, 2 Bara, Maghbazar, Dhaka-1217, Bangladesh

Received Date : 10 February, 2023

Accepted Date : 20 May, 2023.

Other indications are for surgical intervention including discomfort and irritation unresponsive to conservative therapy, and, restricted ocular motility difficulty with contact lens wear, anticipated Kerato-refractive surgery and unacceptable appearance.¹⁰

Materials and methods: -

Study Place:

Pangsha Eye Hospital, Rajbari, a South-Western district of Bangladesh which is relatively warmer and drier than other parts of the country.

Study Period:

Seven years (January 2012 to June 2019)

Study Population:

This case series of primary pterygium included 280 cases; 138 being males and 142 females. Of them, 103 patients were <35 years age-group while 59 were from >56 years. However, almost 42.1% cases were between 31 to 55 years.

Study type:

Observational study: Clinical and Surgical study on patients of primary pterygium

Clinical/ Ophthalmological methods:

The study method included a series of patients with primary pterygium extending at least 3 mm into the cornea. The history was taken and relevant investigations were done in every patient and medical data were reviewed in detail. Major systemic conditions were excluded such as severe diabetes mellitus, uncontrolled Hypertension, Collagen vascular disease and one-eyed patients.

Eye Examination/ Ophthalmological procedures:

A complete ophthalmological examination using slit lamp bio-microscopy, intraocular pressure measurements and visual acuity was performed to rule out Glaucoma, Vitreo-retinal disease, dry eye and other minor lids and ocular abnormality which may influence over the surgical procedures and operation outcome. All patients were followed up on the 1st post-operative day, after 1 week; 3rd weeks and 2 months up one year.⁴

Time of recurrence after operation:

All of 11 patients after pterygium had excision with amniotic membrane grafting within 6 months after surgery. Conjunctival grafts had a better yield in terms of pterygium recurrence as well as overall recurrence time as conjunctival grafts, including limbus stem cell grafts, inhibit the effect on the remaining abnormal tissue and

help in restoration of limbal barrier with the help of limbal stem cells, resulting in reduced frequency and duration of pterygium recurrence.¹¹

A study showed that, after stem grafting; recurrence of pterygium growth was only present in two cases (4.75%).¹²

Surgical procedure:

Pterygium excision was done by a single surgeon in same hospital under local peribulbar anesthesia or subconjunctival anesthesia of 2% lignocaine containing 1:10,000 adrenalin.

The head of the pterygium was first separated at the limbus and dissected toward central cornea with a pair of spring scissors. After excision of head and most of body, Tenon and sub-conjunctival fibro-vascular tissue were separated from the overlying conjunctiva, undermined and excised extensively upward and downward towards the formic and medially towards but not reaching the curuncle; caution was taken not to damage the medial rectus.

Cautery was gently applied to bleeding vessels. The conjunctiva above and below the pterygium was trimmed to create a rectangular area of bare sclera. Residual fibro-vascular tissue over the cornea was detached using toothed forceps or by gentle scraping with a 15 surgical blade. The bare sclera was covered with amniotic membrane, which was oriented with base membrane side up. The amniotic membrane was sutured through the episcleral tissue to the edge of the conjunctiva along the bare sclera border with seven to eight interrupted 10-0 silk monofilament sutures and the eye was patched. Post-operative Moxifloxacin and Dexamethasone eye drop were administered 6 time daily and some patient complain irritation from stitches and those cases were managed by lubricants. There after eye drops were tapered as per need. Patients were following after 7 day, 3 weeks after 2 months and up to 6 months. Complications such as recurrent pterygium, epithelial defects, dullen formation and photophobia were recorded.

Result:

Total 280 eyes of 272 patients with primary pterygia of consecutive patients including 138 (49.29%) male and 142 (50.71%) female subjects with mean age of 48.36 ± 10.76 (range 18-72) years were operated 170 (60.71%) patients had occupations with considerable exposure to actinic damage. now a day woman is also involved in outdoor work as like as male. In our study total patients received for pterygium operation majority patients were

female 142 (50.71%). The extent of pterygium invasion beyond the limbus ranged from 5.5 \pm 1.6 range 3-8 mm.

On the first postoperative day, all patients had corneal epithelial defects, by one week, all epithelial defects healed completely and there was no conjunctival staining with fluorescein. None of the patients had any significant change in intraocular pressure in any time during follow up period.

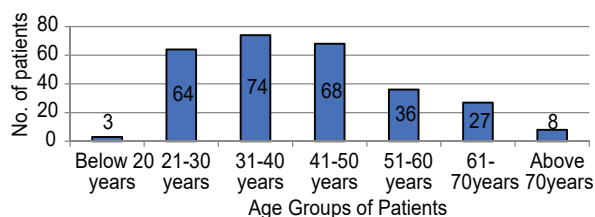
Pre-operative, best corrected visual acuity for most patient 6/18 to 6/12 two or more lines of visual improvement. The recurrence rate was 4% (11patients) of 280 cases over follow up period of 6 months.

Section I: Socio-Demographic characteristics of 280 Pterygium Patients:-

Table I
Distribution of patients by their age

Patients' age	No of patients	Percentage
Below 20 years	03	1.07%
21-30 years	64	22.86%
31-40 years	74	26.43%
41-50 years	68	24.29%
51-60 years	36	12.86%
61- 70years	27	9.64%
Above 70years	08	2.86%

This above Table -I shows the age distribution of 280 pterygium patients. This reflects that younger age Groups are more affected with this disease. 19 years to 50-year age group are mostly affected 209 out of 280 (74.64%). On the study 16 year to 50 years age group 142 out of 212 (66.98%).¹³



Above two study is done in same institute and area, surgery was done by same surgeon.

In a previous study, in 2018, 18 years to 58 years age group patients was 65%.¹¹

The above table shows the age specific distribution of 280 pterygium patients. The younger groups were more affected with pterygium, indicating the patients underwent amniotic surgery in infected eyes. The accompanying pie chart of the table depicts the age distribution of patients graphically.

Table II
Sex distribution of patients by gender (Amniotic membrane Grafting)

Sex	Male	Female	Total
No of patients	135	145	280
Percentage	48.2	51.8	100.0

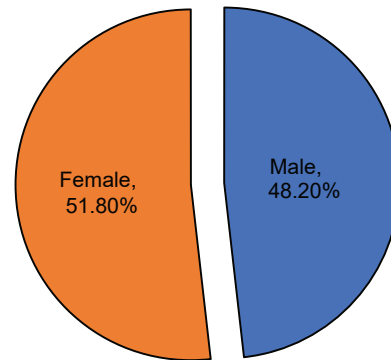
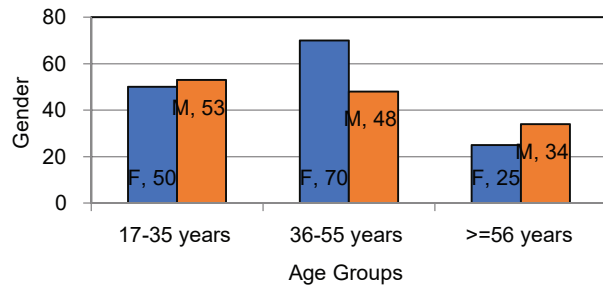


Table-II shows the gender distribution of 280 pterygium patients. This reflects that approximately 52% females were more affected with pterygium than the counterpart (48%). The accompanying pie chart depicts the same graphically as well.

Table III
Association among the age groups and genders of pterygium patients

Age Group	Gender		Statistical Association, P-value
	Female (n=145)	Male (n=135)	
17-35 years (n=103)	50	53	$\chi^2=5.211$, P-value=.074, df=3
36-55 years(n=118)	70	48	
>=56 years(n=59)	25	34	

Table-III yields no association patients age groups with the sex of Pterygium patients ($p=.074$) having enough evidence not to reject any association, statistically.



The following figure below depicts the same making it obvious in bar diagram for more visibility.

Table IV

Distribution of pterygium patients by their occupations

Occupation	No of patients	Percentage
Farmer	105	37.5%
Home maker	110	39.29%
Service holder	25	8.93%
Business	18	6.43%
Teacher	12	4.28%
Student	10	3.57%

According to table IV, it had become obvious that pterygium was highest found among the home maker (~39%), followed by farmers as the next riskiest professions (37.5%) having pterygium. Female worker in outfield is increasing day by day. People today not able to depended alone single working arena due

economical point of view. Teacher, business man, service holder even students are participating in outdoor work. So, now-a-days it is very difficult to differentiate occupational landmark of pterygium. The concurrent pie chart of the table-IV reflects the similar data but in a more obvious visual effect for the pterygium patients.

Section II: - Details of ophthalmological issues and surgery (pterygium) performed

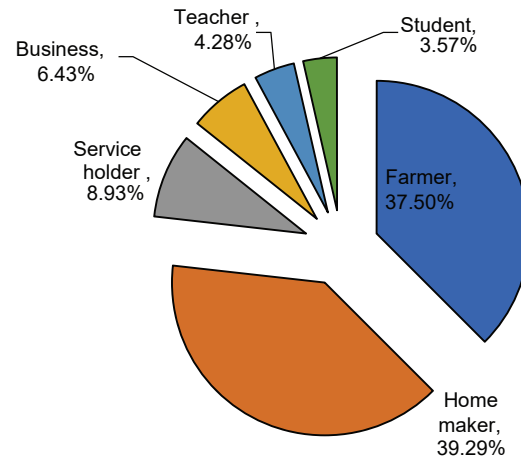


Table-V shows that the pterygium surgeries were performed most (16.4%) in 2018 followed by in 13.6% in 2019 and 14.3% in 2013 & 13.9% in 2015, and 12.5% in 2014 & 11.4% in 2017. However, a bit lower case was done in 2012 & 2016 being 9.6% & 8.2% respectively.

The figure below depicts the same data but making it more visible in graphical representation.

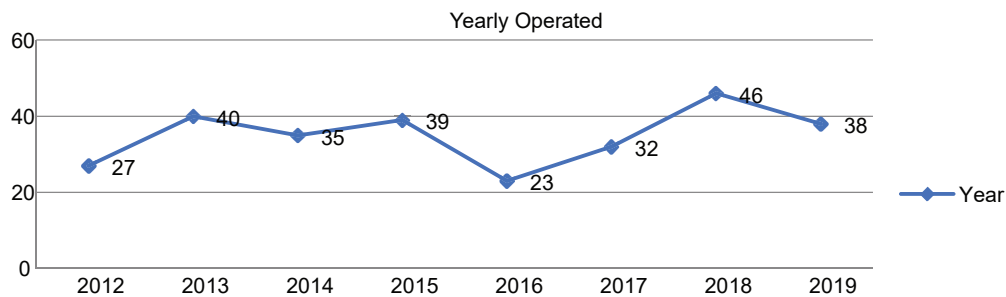


Table V

Distribution of patients by the years of operations (Amniotic membrane Grafting)

Year	2012	2013	2014	2015	2016	2017	2018	2019	Total
No of patients	27	40	35	39	23	32	46	38	280
Percentage	9.6	14.3	12.5	13.9	8.2	11.4	16.4	13.6	100.0

Table VI*Recurrence in after Amniotic membrane-graft: 11 in 280 cases*

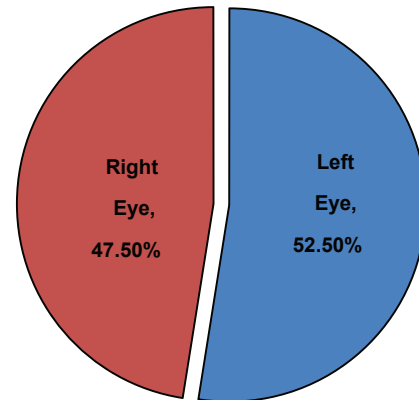
Gender	Total no	Percentage
Male	06	54.55%
Female	05	45.45%

Recurrence rate is a little high in male patients. It may early exposure of sunlight after operation as the male patients of rural area avoid black goggles and anomaly of post-operative medication may the important factors. It may need further evaluation regarding this issue.

Table VII*Distribution table of 280 patients affected eye*

Affected Eye	Frequency	Percent
Left Eye	147	52.5
Right Eye	133	47.5
Total	280	100.0

Table-VII, revealed important findings that the pterygium surgery was performed most (~72%) in patient's left eye than their right one (~28%). The concurrent pie chart reflects the percentage of infected eyes with pterygium to make it more obvious on the difference of surgery done mostly in patient eyes.

**Table VIII***Association among years and age groups of pterygium patients*

Year	Age Groups of Patients			Statistical Association, P-value
	17-35 years(n=103)	36-55 years(n=118)	≥56 years(n=59)	
2012 (n=27)	16	8	3	$\chi^2=25.324$, P-value=.031, df=14
2013 (n=40)	19	16	5	
2014 (n=35)	12	13	10	
2015 (n=39)	12	17	10	
2016 (n=23)	12	5	6	
2017 (n=32)	9	13	10	
2018 (n=46)	9	27	10	
2019 (n=38)	14	19	5	

Table-VIII portrays that there is a significant association in Pterygium operation by years and age groups ($p < 0.03$). It is also proved through seeing the data distribution between years of operations and age groups of patients. The younger groups were more operated surgery for this disease in comparison of elderly group (≥ 56 years ($n=59$)). The obvious visual effect of the above table is shown through the following bar diagram.

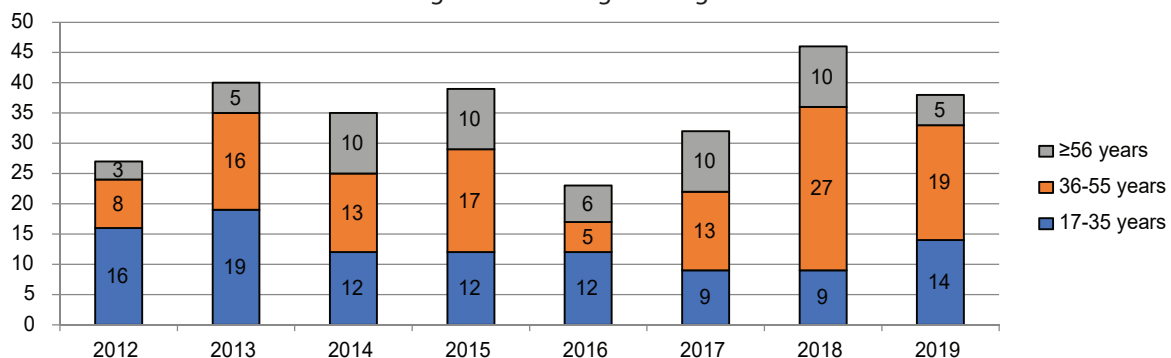
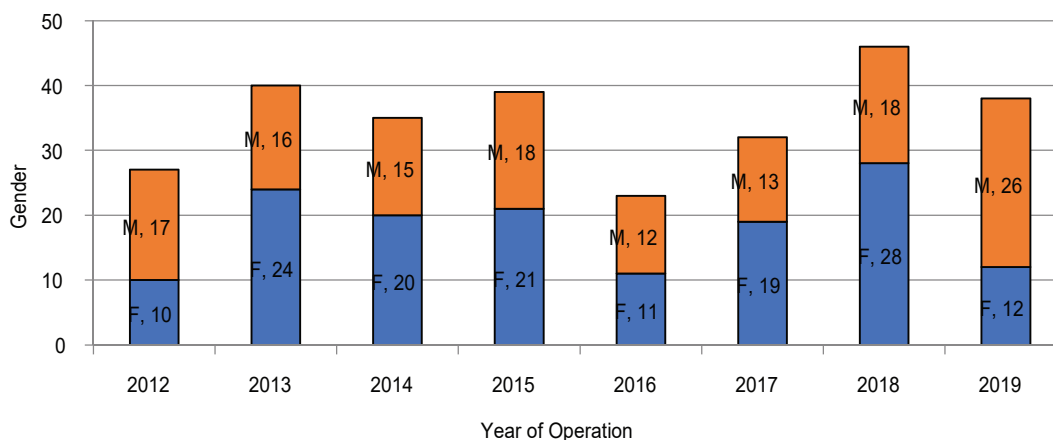


Table IX*Association table of 280 patients' between year and sex of patients*

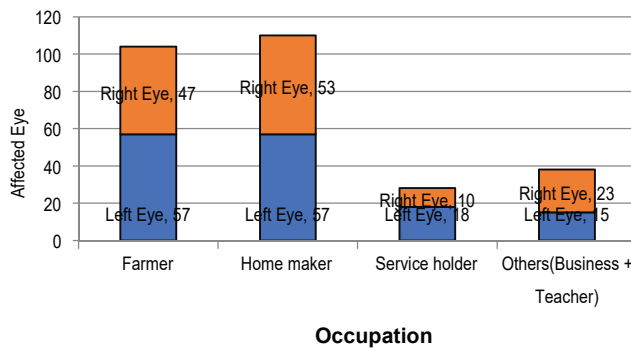
Year	Sex of Patients		Statistical Association, P-value
	Female (n=145)	Male (n=135)	
2012(n=27)	10	17	$\chi^2=12.519$, P-value=.085, df=7
2013(n=40)	24	16	
2014(n=35)	20	15	
2015(n=39)	21	18	
2016(n=23)	11	12	
2017(n=32)	19	13	
2018(n=46)	28	18	
2019(n=38)	12	26	

Table-IX picturing that there was no association of year of operations with gender of patients as the p-value=0.085 which is greater than 0.05 providing enough evidence not to reject no association between these two variables of this study.

**Table X***Association table of 280 patients between occupation and Pterygium of eyes*

Occupation	Eye		Statistical Association, P-value
	Left Eye(n=147)	Right Eye(n=133)	
Farmer(n=104)	57	47	$\chi^2=4.388$, P-value=.223, df=3
Home Maker(n=110)	57	53	
Service Holder(n=28)	18	10	
Others(Business + teacher + student) (n=38)	15	23	

Table-X describes there was no association of occupation of patients with infection of eyes as the corresponding p-value=0.223 which is greater than 0.05. Left eye is likely to be infected most in home maker and secondly infected most in farmer. From this table, students are less likely to be affected in right eye.



Discussion:

Pterygium is a wing-shaped, fibro-vascular growth of bulbar conjunctiva that crosses the limbus and extends over peripheral cornea- that may cover central parts of cornea causing severe visual impairment.¹ However, less studies on pterygium- a common external eye condition have not been reported among Bangladeshi population, though it affects other populations in the tropical and subtropical regions varying with a prevalence of 2%-7%.² But, invasion of corneal surface can lead to significant visual impairments, irritation of ocular surface, or lead to irregular astigmatism, obstruction of visual axis and loss of corneal transparency, incidence/prevalence of which may vary among different age, sex, and geographical location.³ Though worldwide prevalence of pterygium has been reported up to 10.2%,³ ranging from 2.8%⁴ to 33%,⁵ findings of our study based on a rural district, yielded it among 50% patients: 49% in males & 51% in female patients with a mean age of 43.4 ± 10.9 years.

Though nasal limbus, reportedly, remain commonest site of pterygium formation (due to predilection attributed to focus of light passing through anterior chamber causing damage to limbal stem cell and oxidative stress,⁶ ⁻⁷ we observed pterygium extended on to corneas for 4.76 ± 1.4 mm (range 3 to 8) mm in our patients.

Occupation of 37.5% of our rural patients were farmers who are to work outside in farming fields direct under the sun (UV-ray)- an observation that agrees with several population based studies revealing association between pterygium formation and outdoor occupation/activities, most likely a result of exposure to ultraviolet radiation, as the prognosis reported by Di Giroloma N and Chui J.⁸⁻⁹

Pterygium is a multifactorial degenerative corneal disorder. Different procedures have been proposed for treatment of the condition, the main complication common to all is recurrent disease which is more difficult to control.¹⁰ It is believed that surgical trauma and postoperative inflammation activate sub-conjunctival

fibroblast and vascular proliferation, and deposition of extracellular matrix proteins, all of which contribute to recurrence of the lesion.¹⁴ Conjunctival auto graft were superior to that of bare sclera technique.¹⁵

In our study, yielding lower recurrence rate and favorable safety profile of pterygium excision with AMT attested the efficacy of this treatment modality and compare favorably with previous reports due to removal of sufficient conjunctival and sub-conjunctival fibro vascular tissue, especially adjacent to the limbus- which has been elaborated, which has been elaborated in other study.¹⁶

On strategy of decreasing pterygium recurrence is the use of conjunctival auto grafts, that Kenyon et al reported a recurrence rate of 5.3% after fixation of pterygium with conjunctival auto grafts¹⁷ in a randomized clinical trial, which remains similar with our findings, demonstrating only **4% eyes to have faced with recurrent pterygium**. However, Lewallen¹⁸ reported 40% recurrence rate with the bare sclera technique versus 7% with conjunctival auto grafts, **as we followed in our patients in this study**. Intraoperative application of mitomycin C to sclera bed is another strategy which has gained increasing acceptance but entail several complications.¹⁹⁻²⁰

The recurrence rate after amniotic membrane transplantation was initially reported to be 10.9% for primary and 37.5% for secondary pterygium, being much higher than recurrent rates of conjunctival auto grafts,²³ reducing to 3% and 9.5% respectively, after modifying the surgical technique,²⁴ which compared favorably with conjunctival auto grafts¹⁴ being superior to that of bare sclera technique²⁵ that we have followed in our study as Fallah et al²⁶ performed for treatment of recurrent pterygia. Matin et al showed that amniotic membrane graft alone is effective adjunctive treatment for recurrence pterygia and the addition of intra operative mitomycin c did not further reduce recurrence rates.²⁷

Nakamura²¹ reported that freeze-dried amniotic membrane demonstrates excellent Biocompatibility on the ocular surface. This biomaterial may be considered as an alternative to Conjunctival grafting in the treatment of pterygium. Promotion of conjunctival epithelium wound healing suppression of fibroblasts and reduced extracellular matrix production are thought to be the major mechanism by which amniotic membrane transplantation inhibits recurrence of pterygium.²²

To date, there has been no report of sight threatening complications following amniotic membrane transplantation. Minor complications such as conjunctival epithelial inclusion cyst formation, caused by embedded conjunctival epithelium, occur more frequently with conjunctival autografts as compared to AMT. However, amniotic membrane contamination remains a potential risk which cannot be overlooked.¹¹⁻¹³

The low recurrence rate, favorable safety of pterygium excision with AMT in the current study attest to the efficacy of this treatment modality and compare favorably with previous reports on mitomycin C augmented pterygium excision. We believe that the low recurrence rates were due to removal of sufficient conjunctiva and sub-conjunctival fibro-vascular tissue, especially adjacent to the limbus. Coverage of a larger area by amniotic membrane in turn may promote the proliferation and differentiation of residual normal limbal epithelial cells, which may turn have an inhibitory effect on fibro-vascular ingrowth.¹² The major limitation of the study is the lack of a control group. We prefer AMT over conjunctival autografts because of faster healing time, less discomfort and acceptable recurrence rate, and believe that amniotic membrane transplantation is an appropriate treatment modality for the surgical management of primary pterygia. This may be particularly advantageous for patients with glaucoma who require intact conjunctiva for future glaucoma procedures.

The primary objective in pterygium surgery is to remove the fibro-vascular growth that will eventually produce permanent scarring in the pupillary axis and reduce recurrence. In addition, the surgeon should aim to minimize surgery-related complications, increase patient comfort in post-operative period, and achieve an acceptable cosmetic outcome.²⁸⁻³⁰ However, the various modalities used in the treatment of pterygium have focused mainly on reducing the recurrence. Currently, human fibrin glues have additional useful applications in ophthalmic surgery to minimize the use of sutures and prevent suture-related complications.³¹⁻³³

Unfortunately, transmission of viruses (parvovirus B19, hepatitis, and human immunodeficiency virus or Creutzfeldt-Jacob agent during surgery continues to be a theoretic risk despite viral inactivation techniques.³⁴

The earlier report¹⁸ has shown the average surgical time with the use of fibrin glue as 15.5 min, which was comparable with the current study (11.2 min for the fibrin

glue group). Although the authors did not perform a statistical evaluation of the symptom scores. They stated that the post-operative period was generally comfortable in all patients. In our study, we used the same five-point scale and observed significantly fewer symptoms with the use of fibrin glue compared with suturing. These findings were also consistent with the study of conjunctiva autografts using fibrin glue, in which a number of different symptom scales have been used.³⁵⁻³⁹

Shortening the surgery time and improving post-operative comfort may have several advantages. First, the use of fibrin glue removes the need for tedious suturing process, the learning curve may be shortened, and better results may be more consistently achieved despite differences in the surgical expertise. Second, more rapid and efficient surgery may reduce the risk of infection and save the surgeon and the facility valuable operating room time. And third, from the patient's standpoint, greater comfort allows a more rapid return to their normal lifestyle and productivity.

The disadvantage, when fibrin glue is used, the retraction of the host conjunctiva or graft may result in gap formation between the grafts in the early post-operative period. It is suggested that rapid epithelialization of amniotic membrane prevents post-operative inflammation and thereby reduces the recurrence rate.¹⁸ Thus, attempts of tucking in amniotic membrane under surrounding conjunctiva or pinching it together with recipient conjunctiva were tried to achieve good apposition.^{40,41}

Prospective series in the literature report recurrence rate of 3-40.9% after primary pterygium surgery using suture⁴² have found that single-layered amniotic membrane was able to reduce the recurrence rate to 12.5% which was comparable with this study.

They stated that the addition of mitomycin C did not further reduce the recurrence rate. Moreover, the use of mitomycin C may result in serious complications and is commonly reserved for the recurrence cases. Study reported a lower recurrence rate (3%).⁴³

When AMT was combined with intra-operative triamcinolone, depot steroid has been reported to be effective in decreasing post-operative inflammation and preventing pterygium recurrence.⁴⁴ In this study, we used intra-operative triamcinolone and found the recurrence rates as 9.4% in the fibrin glue group and 10.5% in the suture group.⁴⁵

Conclusion: -

Excision of pterygium with Amniotic membrane grafting remains a good alternative and effective treatment options after conjunctival auto graft.

Conflict of interest: None.

Acknowledgement:

The authors remain grateful to the authority of Ad-din Women's Medical College and Hospital, and, Dept. of Gynecology for assisting to manage amniotic membrane and dept. of ophthalmology and staff of Pangsha Eye Hospital Computer and Record Keeping Section for unconditional support and encouraging in these procedures. Thanks a lot to all patients who participate and assisted us in data collection for further analysis.

Reference:

- Duane TD, jaeger EA, Tasman W. Duane's Ophthalmology, Philadelphia, PA. Lippincott Williams and Wilkins, 2009)
- Rong SS, Peng Y, Ilang YB, Cao D, Jhanji V. Does cigarette smoking alter the risk of pterygium? A systematic review and Meta-analysis. Invest Ophthalmic Vis Sci. 2014; 55(10):6235-6243.
- Liu L, WU j, Geng j, Yuan Z, Huang D. Geographical prevalence and risk factors for pterygium; a systemic review and meta-analysis. BMJ Open. 2013;3(11): e003787.
- WU K, He M, Xu, J, Li S. Pterygium in aged population in Doumen county, China. Yan KeXueBao. 2002. 18(3):817-827. (4)
- McCarty CA, Fu CI, Taylor HR. Epidemiology of pterygium in Victoria, Australia. Br J Ophthalmol. 2000; 84 (3). 289-292.
- Chui J, Coroneo MT, Tat LT, Crouch R, Wakefield D, Girolamo N. Ophthalmic Pterygium. A stem cell disorder with premalignant features. Am J Pathol . 2011;178(2) 817-827.
- Alqahtani JM. The prevalence of pterygium in Alkhobar; a hospital based study, J Family Community Med 2013;20(30) 159-163.
- Di Girolamo N, Chui J, Coronea MT, Wakefield D. Pathogenesis of pterygia; role of cytokines growth factors, and matrix metallo-proteinases. Prog Retin Eye Res 2004;23(2) 195-228.
- Chui J, Di Girolamo N, Wakefield D, Coronea MT. The pathogenesis of pterygium. Current concepts and their therapeutic implication, Ocul Surf 2008;6(1) 24-43.
- Hirst LW, .The treatment of pterygium. Surv Ophthalmol 2003; 48: 145-147.
- Nukhba Zahid, Ifran Qayyum, Ayesha Hanif. Comparison of recurrence after pterygium Excision with Amniotic membrane graft versus stem cell graft. Pak J Ophthalmol. 2018 vol -34 ,no-1 .
- Riordan-Eva P, Kiel horn I, Ficker L, A, Steele AD. Kirkness CM eye (London) Conjunctival autografts in the surgical management of pterygium. 1993;7 ; 634-638.
- Md Abdul Matin, Kazi Iqbal Hossain, Md Fakrul Islam, Kh Nazmul Huda. J Ophthalmological Society of Bangladesh. Vol 41, No-2: December 2014, pages 206-210.
- MA DH, See LC, Liao SB, Tsai RJ. Amniotic membrane graft for pterygium. Br J Ophthalmol 2000; 84;:973-978.
- Figueiredo RS, Cohen EJ, Gomes JA, Rapuano CJ, Laibson PR Conjunctival autografts for pterygium surgery how well does it prevent recurrence? . Ophthalmic Surg Lasers 1997; 28: 99-104.
- Dua Hs, Gomes JA, King Aj, Maharjan VS. The Amniotic membrane. In: Ophthalmol. 2004; 51-77.
- Kenyon KR, Wagnoner MD, Hettinger ME. Conjunctival autografts transplantation for advanced and recurrent pterygium. Ophthalmology. 1985; 92 (46)-1470.
- Lewallen S.A. Randomized trial conjunctival autografting for pterygium. In: Tropic Ophthalmology. 1989; 1612-1614.
- Mastropasqua L, Carpineto P, Ciancaglini M, Enrico Gallenga, P. Long term results of intra operative Mitomycin C in the treatment of recurrent pterygium. Br J Ophthalmol. 1996; 80; 288-91
- Rubin RS, Pfister RR, Stein RM, Foster CS, Martin NF, Stoleru S. Serious complications of topical mitomycin C after pterygium surgery. Ophthalmology. 1992;99;1647-1654.
- Nakamura T, inatomi T, Sekiyama E, Ang LP, yokoi N, kinoshita S. Novel clinical application of sterilized , freeze-dried amniotic membrane to treat patients with pterygium . aetaophthalmolseand 2006;84; 401-405.

22. MA DH, See LC, Iau SB, Tsai RJ. Amniotic membrane graft for pterygium. *Br J Ophthalmol* . 2000;84: 973-978
23. Prabhasawat P, Barton K, Burkett G. Comparison of conjunctival autografts, amniotic membrane Grafts and primary closure for pterygium excision. *Ophthalmology* .1997;104:974-985.
24. Solomon A, Pires RT, Tseng SCG. Amniotic membrane transplantation after extensive removal of primary and recurrent pterygia. *Ophthalmology*. 2001;108; 449-460.
25. Tekin NF, Kaynak S, Saatci SO. Preserved amniotic membrane transplantation in the treatment of primary pterygium; *surg lasers*;32;464-469.
26. Fallah MR, Golabdar MR, Amozadeh J, Zare MA, Moghimi S, Fakhraee G. Transplantation of conjunctival limbal autograft and amniotic membrane VS mitomycin c and amniotic membrane in the treatment of recurrent pterygium *EYE* 2008;22;420-424.
27. Md Abdul Matin et al pterygium excision with conjunctival autografts is effective and right ways of pterygium treatment. *Journal of ophthalmological society of Bangladesh* 2016: 206-210.
28. Soliman Mahdy MA Treatment of primary pterygium: role of limbal stem cell and conjunctival autografts transplantation.. *Bhatia J Eur J Ophthalmol* 2009;19: 729-732
29. Baradaran Rafi A, Aghayan HR, Arjmand B, Javadi MA Amniotic Membrane Transplantation..
30. Essex RW, Snibson GR, Daniell M, Tole DM. Clin. Exp Amniotic Membrane grafting in the surgical management of primary pterygium.. *ophthalmol*2004; 32: 501-504.
31. Biendner B, Rosenthal G, conjunctival closure in strabismus surgery : vicryl versus fibrin glue. *Ophthalmic surg lasers* 1996; 27:967.
32. Kajirawa K. Repair of a leaking bleb with fibrin glue *.Am Ophthalmol* 1990; 109: 599-601.
33. Mentens R, Stalmans P. Comparison of fibrin glue and suture for conjunctival closure in pars plana vitrectomy . *Am j Ophthalmol* 2007 ; 128-131
34. Chan Sm, Biosjoly H. advances in the use of adhesives in ophthalmology. *curropin ophthalmol* 2004;15: 305-310.
35. Marticorena J, Rodriques-Ares MT, Tourino R, Mera P, Valladares MJ, Martinez-de-la -casa JM et al. pterygium surgery; conjunctival autografts using fibrin adhesive . *Cornea* 2006; 25: 34-36
36. Koranyi G, Seregard S, Kopp ED. The cut and paste method for primary pterygium surgery : long term follow-up . *Acta ophthalmol scand* 2005; 83: 298-301.
37. Uy HS, Reyes JMG, Flores JDG, Lim-Bon Siong R. Comparison of fibrin glue and sutures for attaching conjunctival autografts after pterygium excision . *ophthalmology* 2005; 112: 667-671.
38. Bahar I, Weinberger D, Gatton DD, Avisar R. Fibrin glue versus vicryl sutures for primary conjunctival closure in pterygium surgery : long-term result. *curr eye Res* 2007; 32 : 399-405.
39. Karalezli A, Kucukerdonmez C, Akova YA, Altan-yaycioglu R, Borazan M, Fibrin glue versus sutures for conjunctival autografting in pterygium surgery : a prospective comparative study . *Br J ophthalmol* 2008; 1206-1210.
40. Ain AK, Bansal R, Sukhija J. Human amniotic membrane transplantation with fibrin glue in management of primary pterygia : a new tuck-in technique. *Cornea* 2008; 94-99.
41. Kheirkhah A, Casas V, Sheha H, Raju VK, Tseng SC. Role of conjunctival inflammation in surgical outcome after amniotic membrane transplantation with or without fibrin glue for pterygium . *cornea* 2008 ; 27 : 56-63.
42. Rosen R: Amniotic membrane grafts to reduce pterygium recurrence. *Cornea*. 2018, 37: 189-193.
43. Ghoozi N, Elalfy M, Said D, Dua H: Healing of autologous conjunctival graft in pterygium surgery . *Acta ophthalmol* 2018, 96: 979-88.
44. Tasneem AF, Nayak VI, Balakrishna N, Krithika N, Prasad SN: Randomized controlled study of amniotic membrane graft versus conjunctival autograft in primary pterygium excision. *IP Int J Oculoncoloculoplasty*, 2020, 6: 33-41.
45. Romano V, Cruciani M, Conti L, Fontana L: fibrin glue versus sutures for conjunctival autografting in primary pterygium surgery. *Cochrane Database Syst Rev* 2016.