

Review Article

An Updated Review on Post Dissection Complications in Neck

*Md. Hasan Hafijur Rahman¹, Mansur Alam², Md. Mahmudul Hasan Khan³, Jarin Tasnim Stella⁴, Umama-Binte-Delwar⁵, Najiba Kabir⁶

Abstract

Incidence of oral & laryngeal cancer in Bangladesh is increasing day by day. Neck dissection is the most commonly performed operation in any tertiary level hospital that has Head and Neck surgery and Oncology setup. Metastatic dissemination to lymph nodes of neck occurs frequently in head neck cancers which down grade the patient's curability, shorten 5 years survival and responsible for recurrent disease. To assess complications following different types of neck dissection this cross sectional study was conducted among patients who underwent different types of neck dissection due to cervical nodal metastasis and attended follow up. Common **Immediate complications** were hemorrhage 02 (3.33%), facial oedema 02(3.33%) and thoracic duct injury 02(3.33%). **Intermediate complications** were seroma (6.67%), wound infection 04 (6.67%) and chylous fistula02 (3.33%). **Late Complications** were hypertrophic scar 02 (3.33%) and shoulder syndrome 04(6.67%). There were no perioperative deaths. Incidence of complication can be reduced by skilled surgery, proper indications, proper identification of anatomical planes along with early recognition and treatment.

Introduction

The history of post neck dissection complications and sequel continuing quest to reduce. Since its original description by Crile in 1906 and subsequent popularization by Hays Martin in 1951, the Radical Neck Dissection (RND) remained the standard treatment for palpable or potential cervical metastasis in head and neck cancers. Though it provided a reliable method of treating patients with head and neck cancer, it became increasingly apparent that it carried substantial morbidity, which led to development of modified procedures that attempted to reduce the adverse effects of the classical operation and yet preserve its effectiveness in oncological terms.

As neck dissection surgical techniques have evolved, so have the type and frequency of complications. Due to intricate anatomy and presence of various nerves, vessels and lymphatic channels, neck dissections are particularly prone to various complications.

These complications in addition to prolonging hospital stay result in expensive and time-consuming management, thus increasing overall burden on hospital resources and patient's pocket. Despite being most commonly performed procedure in any head and neck unit, exact incidence of various neurovascular complications and functional morbidities associated with neck dissection have been studied less especially in Indian subcontinent. With this in view, current study was undertaken and patients were studied prospectively for various short-term and long-term neurovascular complications following neck dissection

History of Neck Dissection:

The neck dissection procedures performed today are the result of many years of refinements and modifications of the first description in the English language by Crile in 1906.

The history of neck dissection is fascinating and several historical figures mark the rationale of neck

1. *Registrar, BIHS General Hospital, Dhaka
2. Combined Military Hospital (CMH), Dhaka
3. Associate Professor, Ad-din Women's Medical College, Dhaka
4. Lecturer, Ad-din Women's Medical College, Dhaka
5. Medical Officer (ENT), Ad-din Women's Medical College, Dhaka

Correspondence: Md. Hasan Hafijur Rahman, Registrar, BIHS General Hospital, Dhaka

Received Date : 10 August, 2022

Accepted Date : 20 October, 2022

dissection in its present form. Concepts of cervical lymph node metastases and the incurability of the disease dawned on surgeons in the mid-nineteenth century with publications as early as 1847 by Joseph von Chelius.^{2,15}

In 1880, Theodor Kocher introduced the Y-shaped incision which is still in use today, thus allowing for wide resection of lymph node metastases. Subsequently, in 1951,¹⁶ Hayes Martin from Memorial Hospital New York, popularized the radical neck dissection with a step-wise description of the technique. A decade later, in 1963, the Argentinian Osvaldo Suarez,⁵ introduced the first systematic approach to functional neck dissection (FND).

Due to new insights into lymph drainage pathways, other modifications were also developed during the 1960s, by Shah JP such as the modified radical neck dissection (MRND) and selective neck dissection (SND).⁷ Increasing knowledge of the topographical distribution of metastatic lymph nodes with various primary sites permitted evolution of less radical techniques. Reported by stell.⁹

In these techniques, selective lymph node groups that have the highest risk of containing metastases are removed and they are mainly associated with names such as Richard Jesse⁸, Alando Ballantyne and Robert Byers from Houston. Neck dissection procedure has some complications and avoiding the complications and ensuring better prognosis as well as disease free survival is of utmost importance.

History of Neck dissection Neck dissection or cervical lymphadenectomy is a systemic removal of the lymph nodes and lymph bearing structures including the surrounding fibro fatty tissue from various compartments of the neck. In 1847 Warren first attempted to remove metastatic cancer in the neck.

In 1880³ Kocher described the resection of tongue combined with removal of regional lymphatic via submandibular approach. In 1906 George¹ Crile gave the first description of the standardized anatomic dissection of the cervical lymphatics.¹¹ In 1951 Hayes martin^{4,12} advocated radical neck dissection as the only acceptable procedure for cervical lymph node metastases. In 1966 Bocca of Italy and Ballantine of USA advocated functional neck dissection. They were supported by Dignataro and Jesse. In 1972 Lindberg⁶

advocated selective neck dissection. In 1994 Spirostrong and Shah⁷ advocated limited neck dissection. George Crile described his experience with 1321 operations and advised removal of the lymph nodes in the neck along with the sternocleidomastoid muscle, internal jugular vein and spinal accessory nerve and he essentially standardized the technique of radical neck dissection. The inevitable morbidity to which this bed fuelled an interest in more conservative approaches and during the 1980s and 1990s a number of less radical procedures have been popularized based on the staging of the dissection presentation.

Specific types of Neck dissection and its importance

The neck dissections has been divided into following categories –

- (a) **Radical Neck dissection:** Removal of the lymph node containing levels in the neck (I-V) and Three non-lymphatic structures- spinal accessory nerve, internal jugular vein and sternocleidomastoid muscle.
- (b) **Modified radical neck dissection:** This operation consists of removal of all lymph nodes groups (levels I-V) with preservation of one or more non lymphatic structures. Type 1 modified radical neck dissection preserves the spinal accessory nerve, type 2 preserves not only the spinal accessory nerve but also the internal jugular vein and a type 3 dissection is when the spinal accessory nerve, the internal jugular vein and the sternomastoid muscle are all preserved. This latter operation (type 3 modified radical neck dissection) is also known as a comprehensive or functional neck dissection.
- (c) **Extended radical neck dissection:** Consists of removal of all of the structures resected in a radical neck dissection along with one or more additional lymph node groups or non-lymphatic structures or both. The additional lymph nodes group includes retropharyngeal lymph node, parotid nodes or lymph nodes in level (VI) or (VII). The non lymphatic structures that may be removed included part or all of the mandible, the parotid gland, part of mastoid tip, prevertebral fascia & musculature, the digastric muscle, the hypoglossal nerve and the external carotid artery & skin.

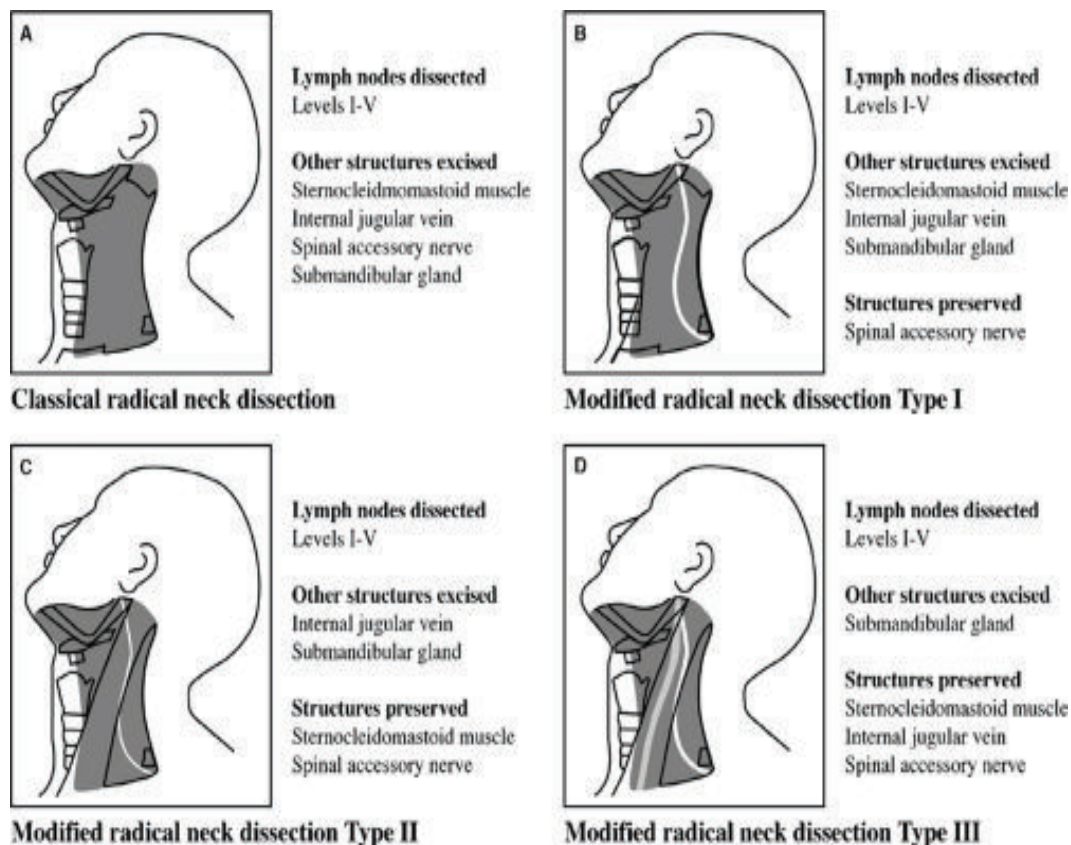


Fig-1: Types of Neck Dissection

Fig.-1: Shows the following characteristics- (a) Classical Radical neck dissection which includes excision of I-V Lymphodes and all important non lymphatic structures. (b) Preservation of spinal accessory nerves (c) Preservation of sternocleido mastoid muscles along with spinal accessory nerves (d) Preservation of sternocleido mastoid muscle, internal jugular vein and spinal accessory nerves

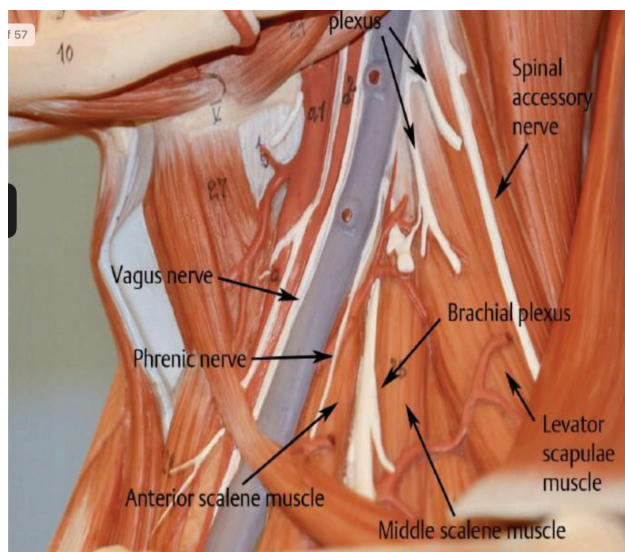


Fig-2: Major Structures of Neck Dissection

Fig-2 shows that identification of significant structures during neck dissection.

Discussion

Metastatic dissemination into the lymph nodes of the neck occurs frequently in cancers of the upper aero digestive tract. More than 50% of patients with identified primary cancers of the head and neck present with obvious metastasis to cervical lymph nodes. The cervical lymphatic plays an active role in the biologic behavior of cancers of the head and neck. The status of neck lymph nodes remains the single most important prognostic factor.

Management of cervical metastatic disease depends on primary site of malignancy and different type of treatment plan (radiotherapy, chemotherapy, adjuvant therapy). Leaving cancer in the cervical nodes, whether or not clinically apparent, inevitably results in unacceptable morbidity and mortality for the patient. There is no treatment more effective for neck metastases than surgery. The choice of treatment of the neck depends on the site and stage of the primary cancer, the

probability of occult metastases, the treatment modality selected for the primary cancer, and the desires of the patient. Neck dissection of different modalities and techniques are the surgical mode of treatment, from selective neck dissection to extended radical neck dissections, form a major part in the management of neck metastases.

Selection of the appropriate surgical procedure for the management of the cervical nodes in a particular patient is based on multiple factors, including the primary site of the cancer, patient status, prior therapy, and treatment goals. Morbidity following different neck dissection e.g. disfigurement, sensory changes, shoulder pain, reduced strength of the trapezius muscle, reduced range of motion of the shoulder, disability in activities of daily life, and even loss of work are common.

Out of 60 cases of neck dissection 50 (83.33%) were male and 10 (16.67%) were female. As the most of the head-neck carcinoma.^{17,21} in our country has been found among male persons, this result corresponds with the other previous studies. Age of the patients ranges from 31-72 years, Mean = 59.1 ± 5.44. The most of the cases were carcinoma of upper aero digestive tract with neck node, which is common in older age group

In other study shown that head-neck carcinoma is more prevalent among the older age group. Most of them were within 5th & 6th decade. The primary site distribution of the patient with neck dissection were occult primary 24 (40%), Thyroid origin 18 (30%), Maxilla 02 (3.33%), Hypopharynx 01 (1.66%), Larynx 08 (13.33%), Nasopharynx 02 (3.33%). Head and neck cancers spread to the lymph nodes of the neck, and this is often the first (and sometimes only) sign of the disease at the time of diagnosis. In this study stage of the neck nodes in patient with neck dissection were N1 02 (3.33%), N2A 08 (13.33%), N2B 22 (36.66%), N2C 06 (10.00%), N3 24 (40%).

Most of the metastatic neck nodes were multiple and size around 3-5 cm in diameter, which were grouped as N2B. Metastatic neck nodes were found level-I 02 (3.33%) level - II 8 (13.33%) level-III in 22 (36.66%) level IV- 4 (6.66%) 18 (30%) level V 02 (3.33%) VI 02 (3.33%). 90% of head and neck cancers are squamous cell carcinomas (SCC), originating from the mucosal lining (epithelium) of these regions.

As Janes Reported.¹⁴ For all types of SCC, the presence of invasion is diagnostic of a malignancy. The clinical (gross) appearance of invasive SCC is quite variable and includes

ulcerated, flat, exophytic, verrucoid, or papillary growths. The histologic appearance of invasive SCC may be as variable as the gross appearance without specific correlation between the gross appearance and the histopathologic findings. Invasive SCC of the upper aero digestive tract includes keratinizing and non-keratinizing carcinomas varying from well to poorly differentiated carcinoma.

In this study there were different types at neck dissection has been undergone such as radical neck dissection¹⁹ were 10 (16.67%), modified radical neck dissection were 22 (36.67%), selective neck dissection were 24 (40%) and extended radical neck dissection were 04 (6.67%).

Although neck dissection is a technically well-established procedure, complications still occur. Intra operative events, such as hemorrhage, loss of a venous suture resulting in air embolism, chylous leakage due to thoracic duct injury, and arrhythmia.

Because of carotid bulb manipulation, are habitually promptly managed; these events may, however, be disastrous for the patient. The surgical wound infection rate was low; preventive antibiotic therapy was given in the preceding 24 hours to surgery. Extensive vascularization of the neck and the uncontaminated nature of the neck surgical field explain this low rate of infection. Factors favoring infection are contamination of the neck when laryngectomy or tracheostomy is done; previous radiotherapy, however, had no negative impact. Chylous leakage is rare; it occurs in 1 to 25% of neck dissection, mostly in the left side.

In this study **immediate complication** were excessive bleeding 02 (3.33%), facial oedema 02 (3.33%) and thoracic duct injury 02 (6.67%). **Intermediate complications** were chylous fistula 02 (3.33%), seroma 04 (6.67%), wound dehiscence 02 (3.33%), wound infection 04 (6.67%) and flap haematoma 02 (3.33%).

Late Complications were hypertrophic scar 02 (3.33%), shoulder syndrome 04 (6.67%), lymph edema 04 (6.67%) and parotid tail hypertrophy 02 (3.33%). The vagus nerve may be injured when the internal jugular vein is ligated during radical neck dissection. If dissection below the ganglion, it results in vocal fold paralysis; if above, there is also dysphagia and aspiration.

This complication is rare, no case was encountered in our series. Phrenic nerve injury is uncommon; it often goes unnoticed, and may result in atelectasis and lung infiltrates. We found no cases of phrenic nerve injury. Accessory nerve injury is not uncommon even when the

accessory nerve is preserved. It is due to skeletonized (and therefore devascularized), which may result in the painful shoulder syndrome and mild to moderate shoulder dysfunction, these affect the patient's quality of life. The Bernard-Honer syndrome or oculosympathetic paresis (blepharoptosis, enophthalmos and miosis) is caused by injury of the cervical sympathetic nerve. This nerve is located posterior to and under the carotid sheath, and may be injured during radical neck dissection; this was not encountered in our series.

References:

1. Crile GW. Excision of cancer in the head and neck. With special reference to the plan of dissection based on one hundred and thirty-two operations. *Journal of the American Medical Association* 1906; 47: 1780-6.
2. Chelius JM. A system of surgery, vol. III Philadelphia: Lea and Blanchard, 1847: 515.
3. Kocher T. Ueber Radicalheilung des Krebses *Deutsche Zeitschrift für Chirurgie* 1880; 13: 134-66
4. Martin H, Del Valle B, Ehrlich H, Cahan WG. Neck dissection. *Cancer* 1951; 4: 441-99.
5. Suarez O. El problema de las metastasis linfaticas y alejadas del cancer de laringe e hipofaringe. *Revue de Otorrinolaringologia* 1963; 23: 83-99_
6. Lindberg R. Distribution of cervical lymph node metastases from squamous cell carcinoma of the upper aero digestive tracts, *Cancer* 1972; 29: 1446-9.
7. Shah JP, Anderson PE. The impact of patterns of neck metastasis on modifications of neck dissection. *Annals of Surgery and Oncology* 1994; 1: 521-32.
8. Jesse RH, Ballantyne AJ, Larson D. Radical or modified neck dissection: a therapeutic dilemma. *American Journal of Surgery* 1978; 136:516-19.
9. Stell P M, Dalby J E, Singh S D, Taylor W. The fixed cervical lymph node cancer. 1984; 53:336-341.
10. Lawrence E, Banister H et al. Lymphatic drainage of head and Neck In: *Grays Anatomy*, 38th edition, ELBS, Churchill Livingstone, 1995; 1611-13.
11. Basmajian JV. Lymphatics of Head and Neck. In: *Gray's Anatomy*: 10th edition, London, Williams and Wilkins, Baltimore. 1980; 542-6.
12. Martin H, Romieu C. Cervical lymph node metastasis cancer. *Surg Gynecol Obstet*. 1995
13. Jesse RH, Pere Z CA, Fletcher GH. Cervical lymph node metastasis. Etiology of unknown primary. 1999; 31:854.
14. Jones AS. Squamous carcinoma presenting as an enlarged cervical node. 2003; 72:1748,
15. Chelius JM. A system of surgery, vol. III. Philadelphia: Lea and Blanchard, 1847: 515.
16. Martin H, Del Valle B, Ehrlich H, Cahan WG. Neck dissection. *Cancer* 1951; 4: 441-99.
17. Watkins John C, Gilbert Ralph W. Stell and Maran's Textbook of Head and Neck Surgery and Oncology, Hodder Arnold: 5th ed. Neck Dissection. 2012; 699.
18. Gleeson M, Scott-Brown's Otorhinolaryngology, Head and Neck Surgery, Hodder Arnold: 7th ed. 2008; 2711-2750.
19. Hossain I A H. Cervical lymphadenopathy-A clinicopathological study of 100 cases. (Dissertation BCPS) 2000. 22. M k Masud, Complication of neck dissection at a Tertiary level Hospital- A study of 30 cases. Mymensingh Medical college 2014.