

# In Search of Gold Standard Treatment of Hemorrhoid

**Dr. Tania Ahmed**

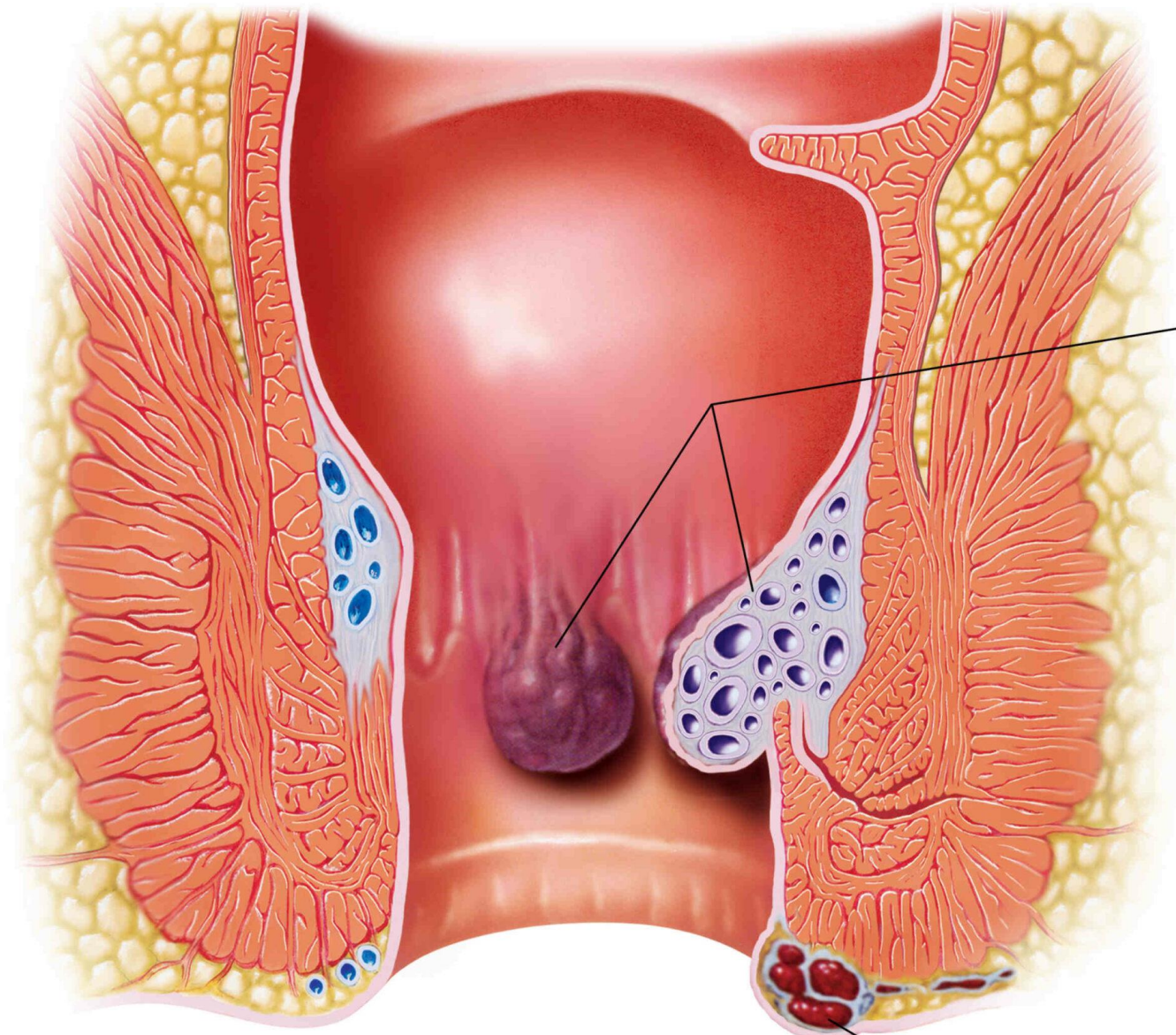
Assistant Professor,

Department of Surgery,

Ad-Din Women's Medical College Hospital, Maghbazar, Dhaka.

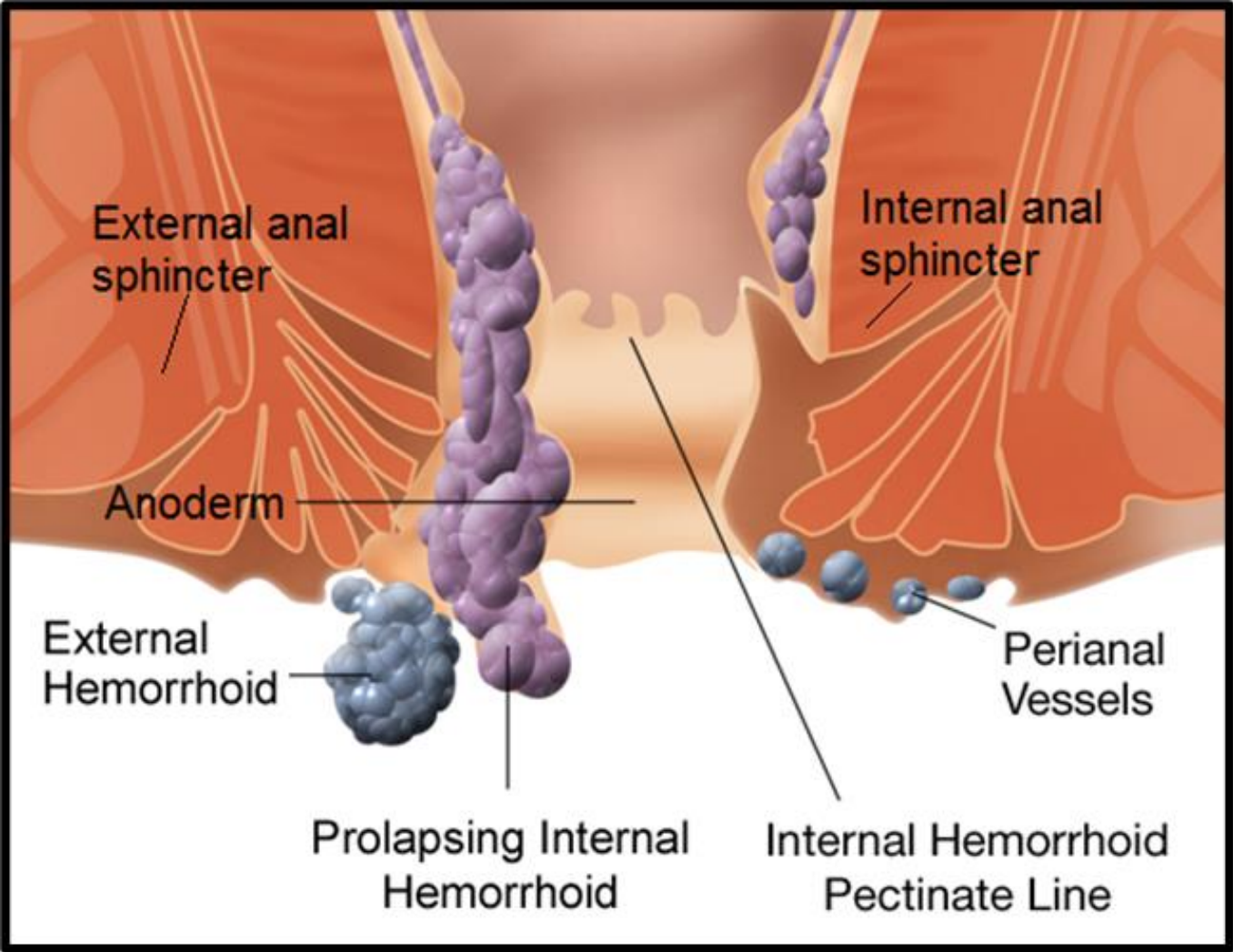
# Definition Of Hemorrhoid

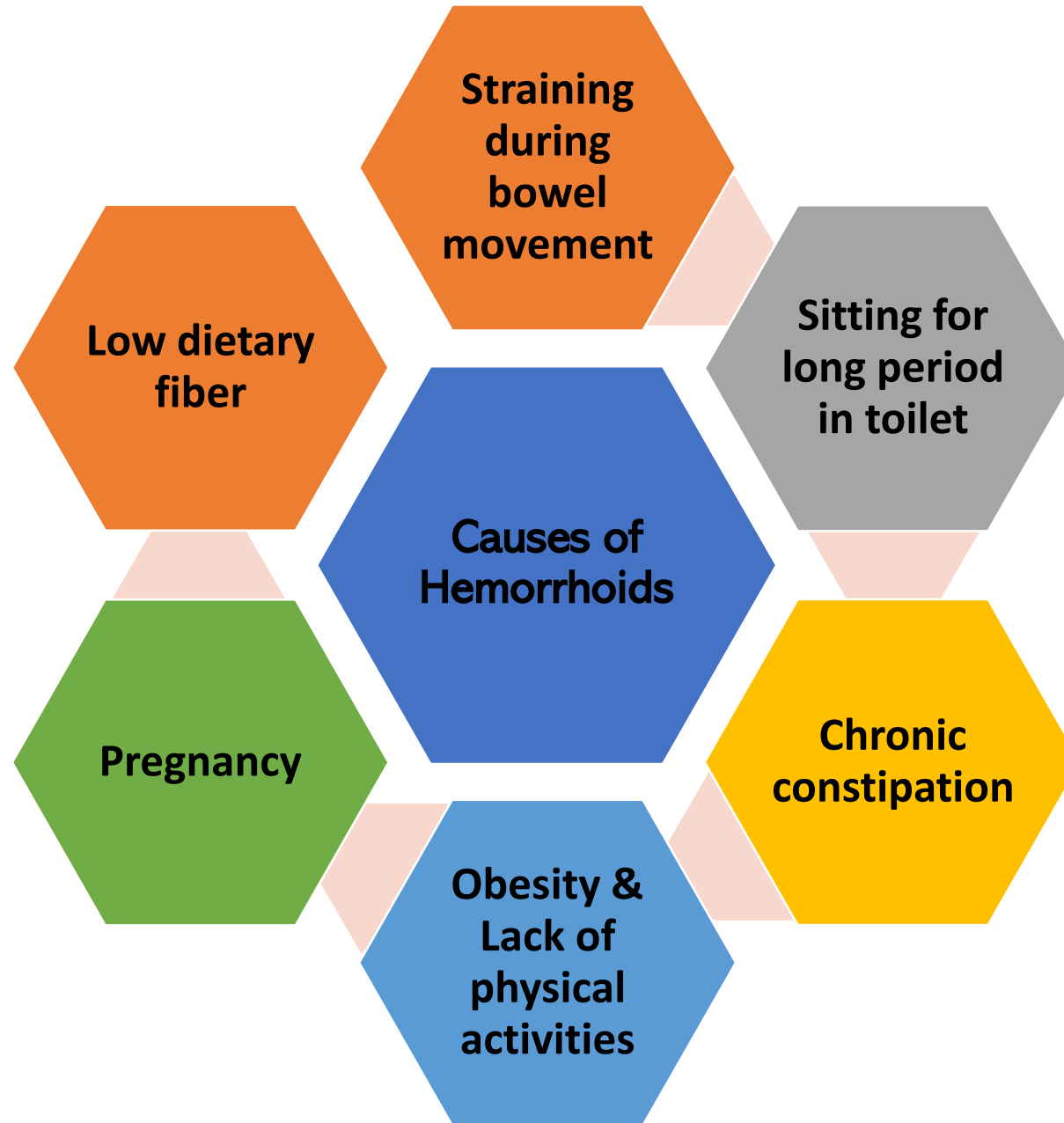
- ❑ Dilated veins of the anal canal



**Internal  
Hemorrhoids**

**External  
Hemorrhoids**



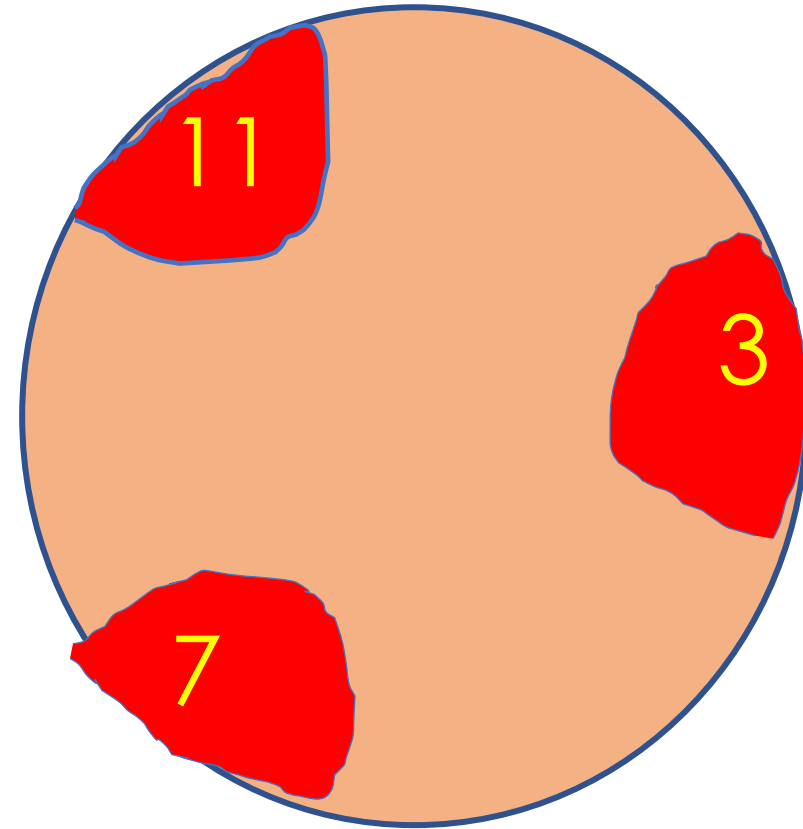
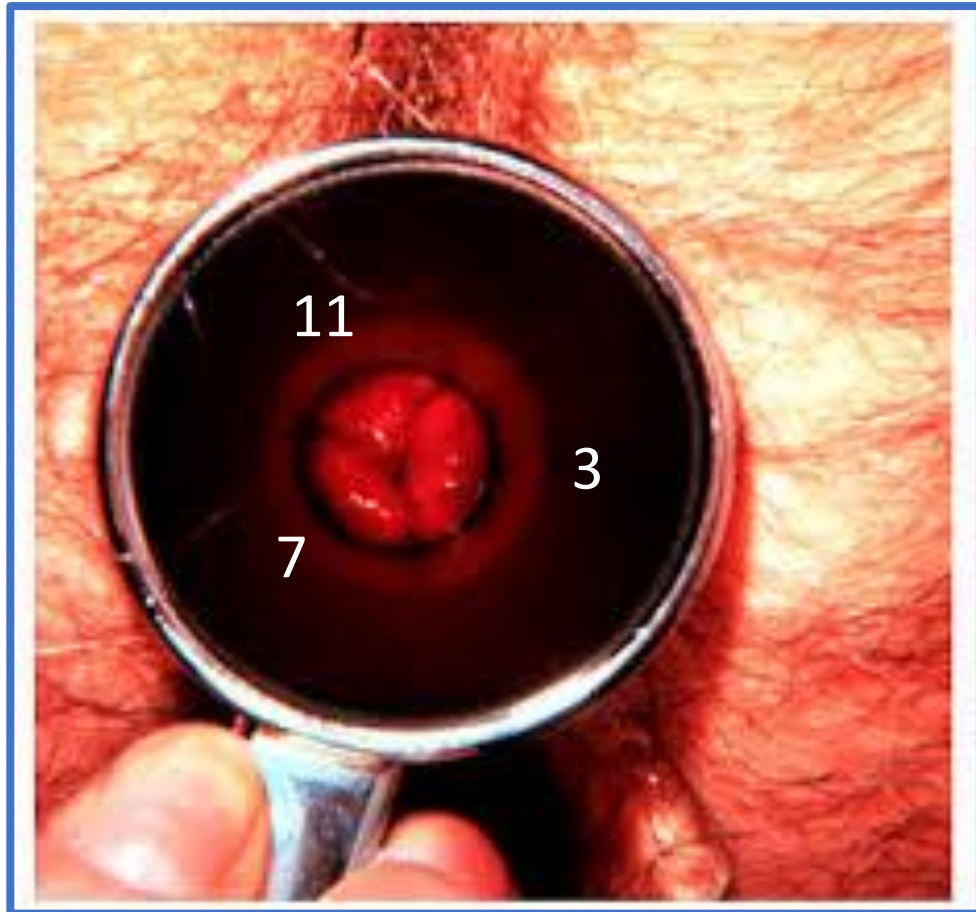

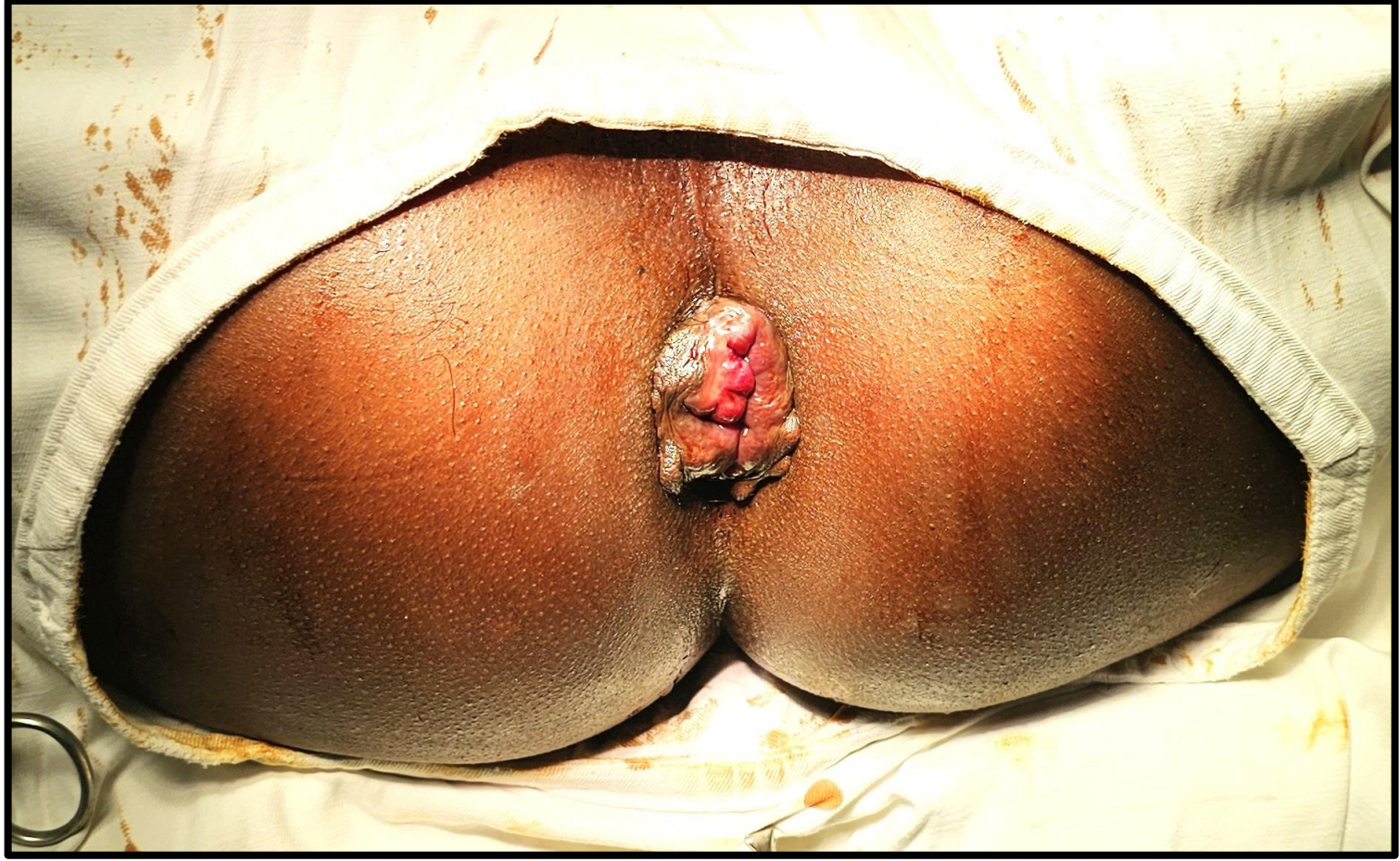# Classification of hemorrhoid

- 1st degree-bleeds only-no prolapse
- 2<sup>nd</sup> degree-Prolapsed but reduces spontaneously
- 3<sup>rd</sup> degree-prolapsed but needs manual reduction
- 4<sup>th</sup> degree-permanently prolapsed



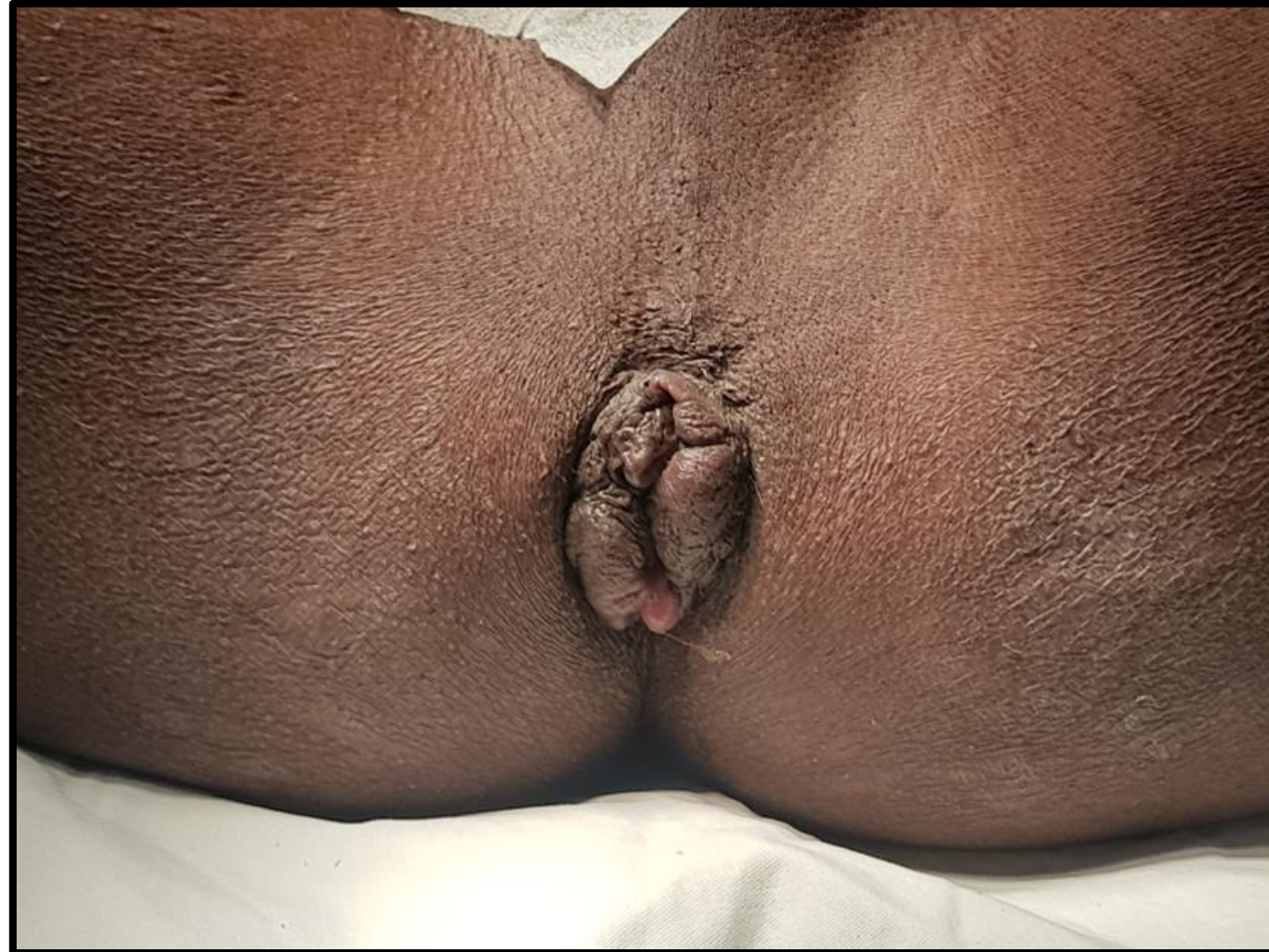# 3, 7 and 11 o'clock position of hemorrhoid on proctoscopy







4<sup>th</sup> degree piles



# Treatment

➤ Conservative-Stool softener, life style modifications, venoconstricting agent etc.

➤ Injection Sclerotherapy

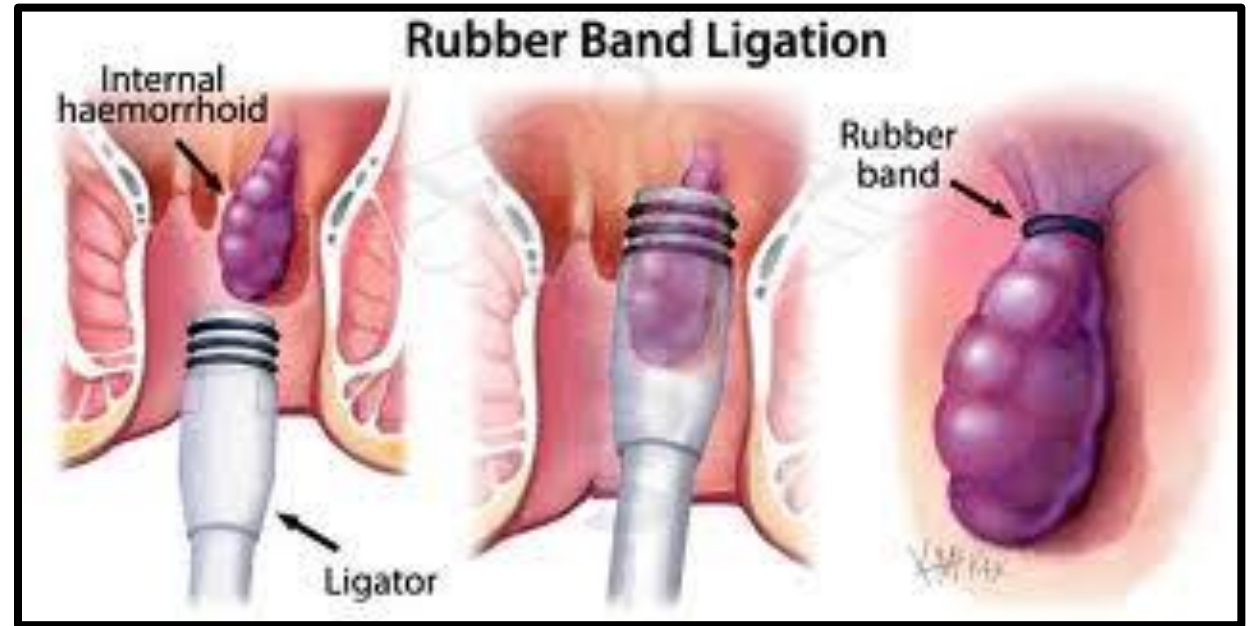
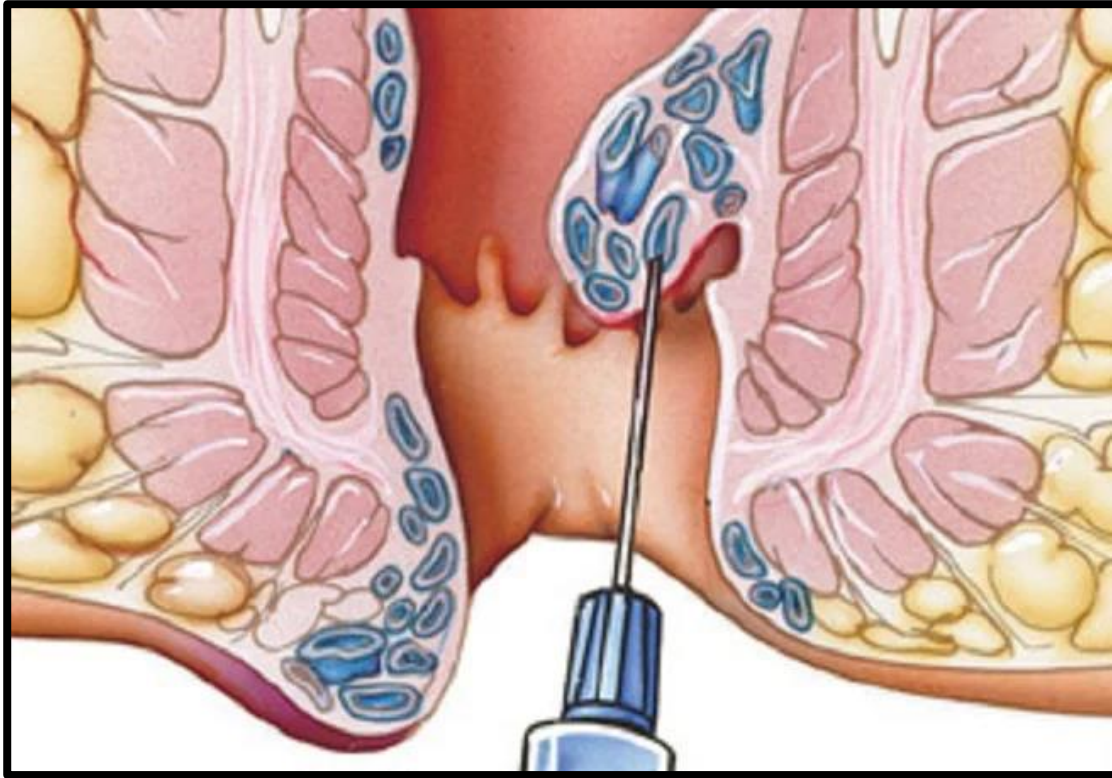
➤ Infra-red coagulation

} 1st degree

➤ Band ligation



2<sup>nd</sup> degree

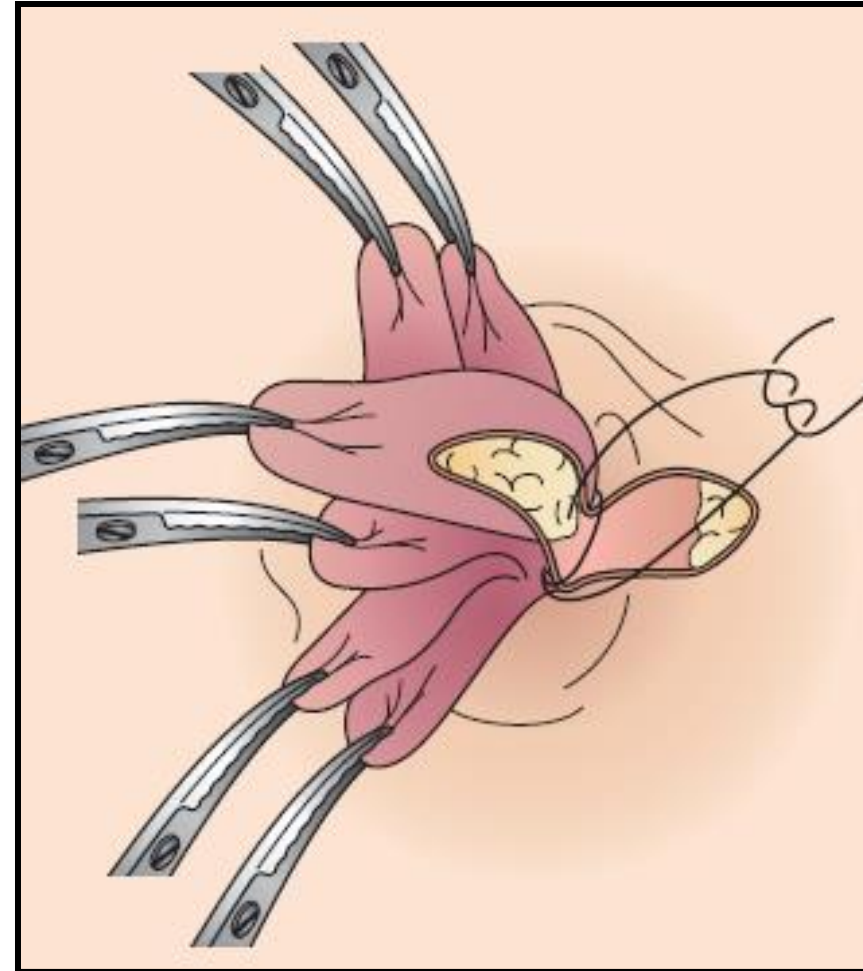
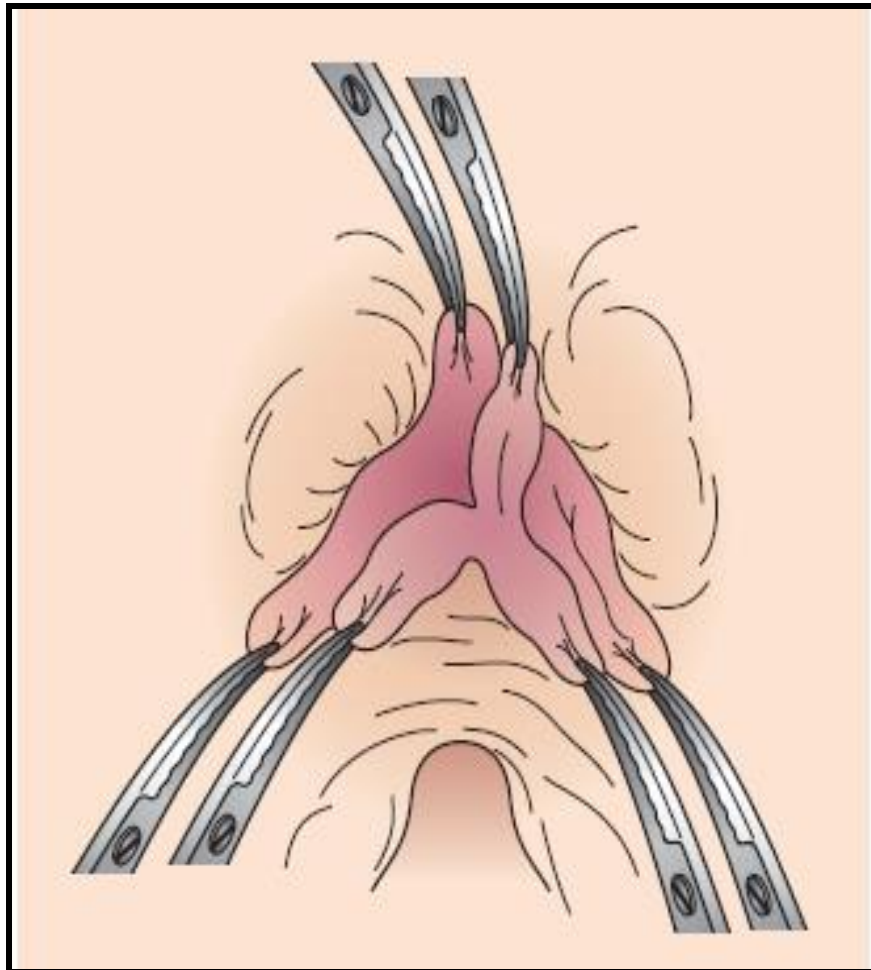


## For 1<sup>st</sup> to 4<sup>th</sup> degree

- Open Hemorrhoidectomy(Milligan Morgan Operation)
- Stapled hemorrhoidopexy
- Laser hemorrhoidectomy
- HAL( Doppler guided Hemorrhoidal artery ligation)

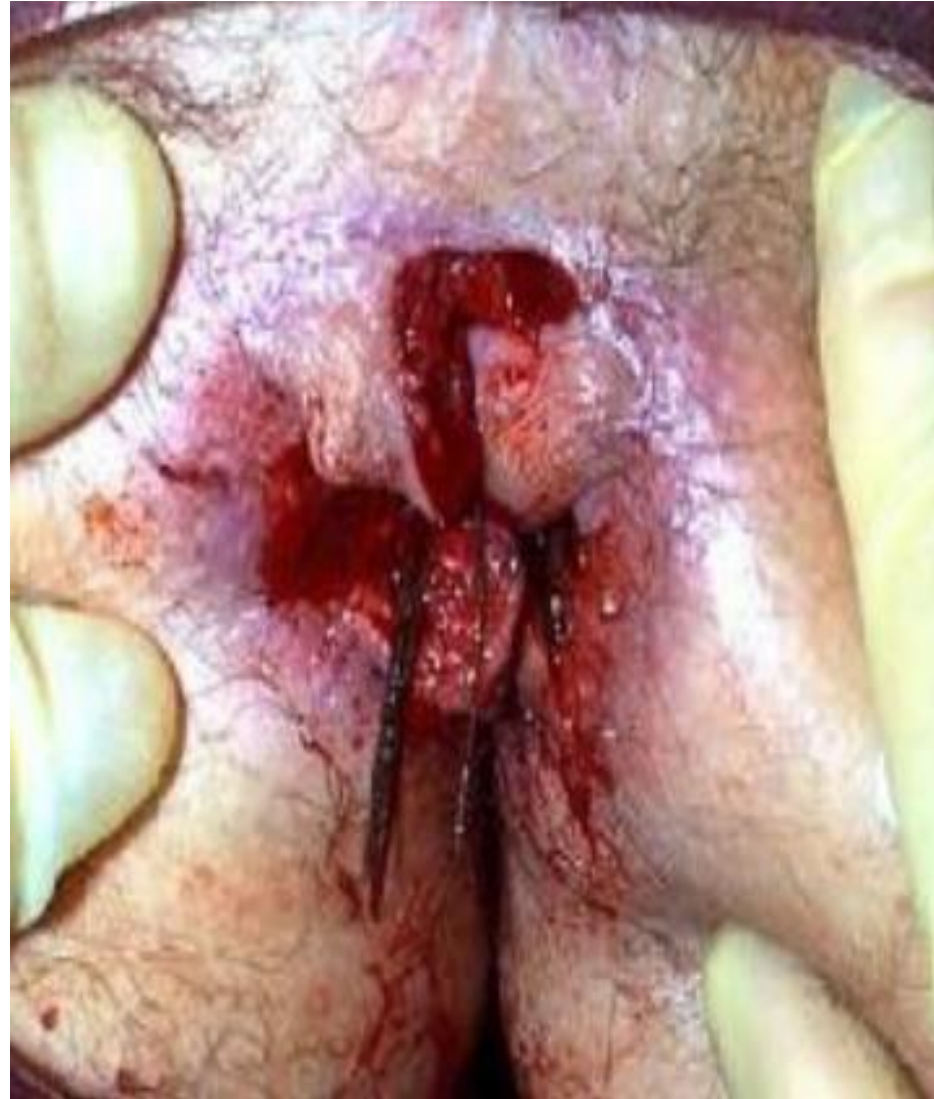

# Steps of Milligan Morgan Hemorrhoidectomy

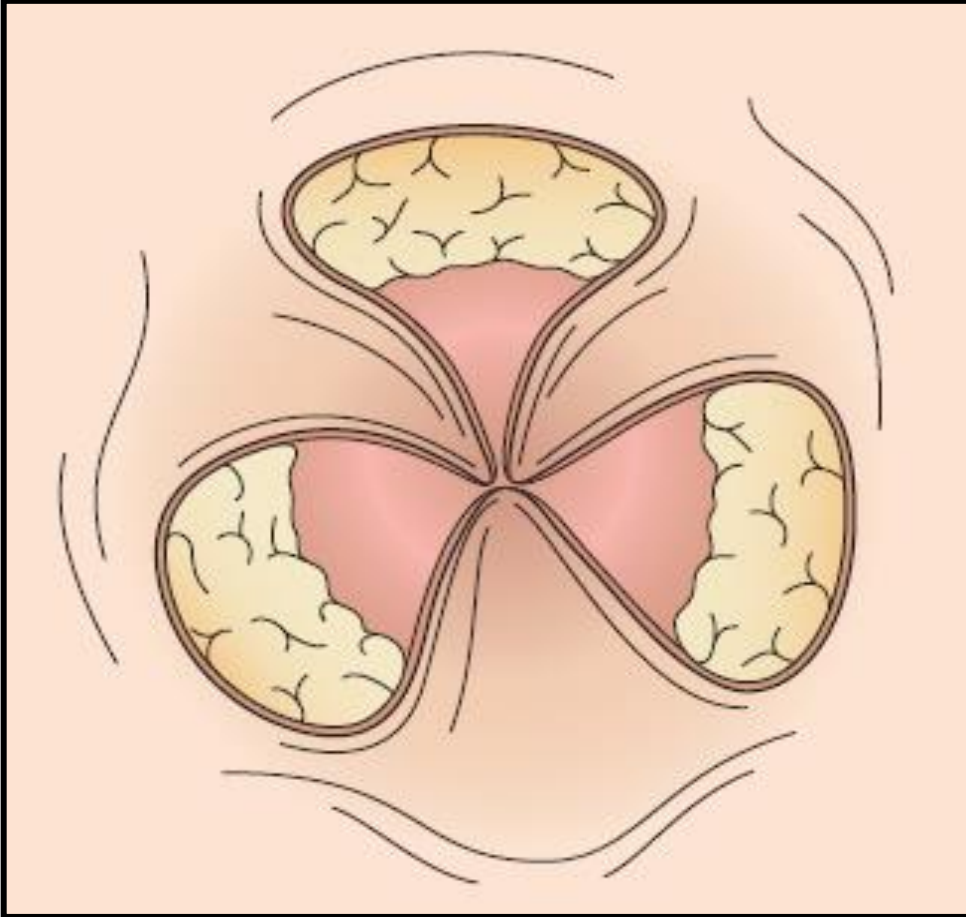




# Postoperative wound after Milligan Morgan



# Post Hemorrhoidectomy Appearance



## Disadvantages

- Healing takes 6-8 weeks
- Pain
- Reactionary hemorrhage
- Wound infection
- Anal stenosis
- Anal incontinence

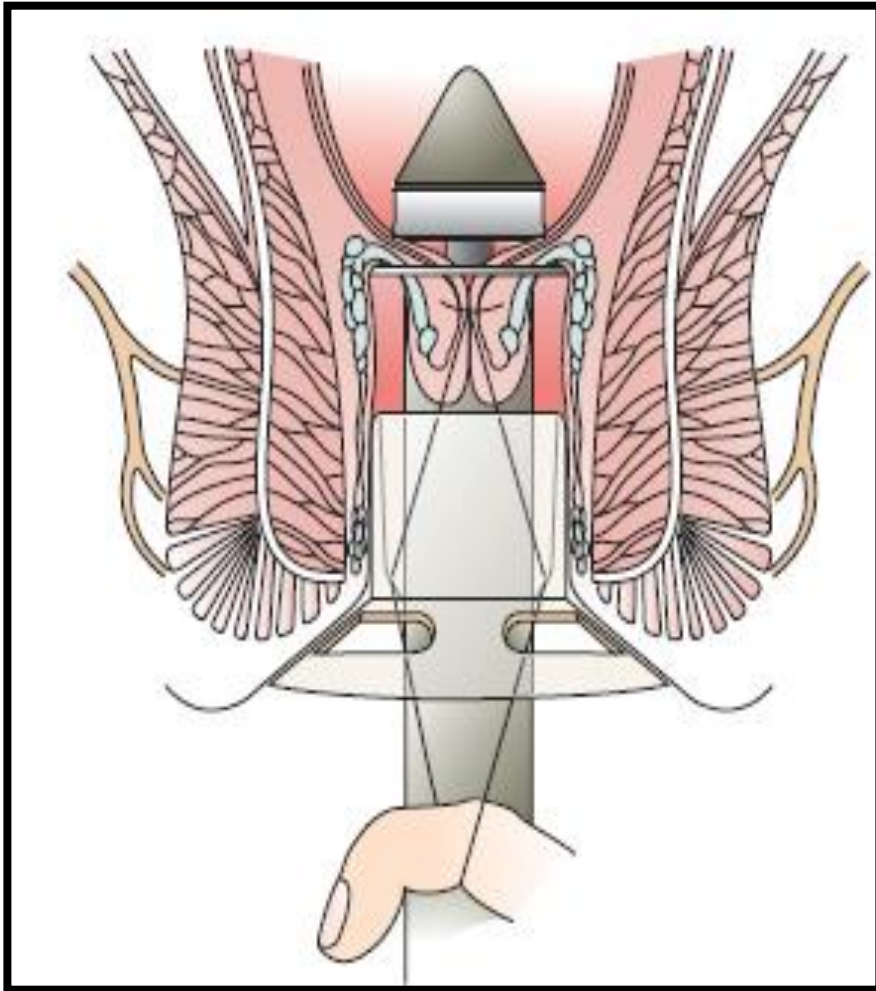
# Principles of Longo Operation

Professor Antonio Longo first described Stapled hemorrhoidopexy in 1998

- Hemorrhoid pedicles are not excised
- Operation is done 2 cm above the dentate line
- A segment of anorectal mucosa and submucosa is excised and stapled by a circular stapler
- Hence no bleeding, no open wound
- Hemorrhoid pedicles are lifted off
- Blood supply to hemorrhoids are cut off
- Hemorrhoid shrinks

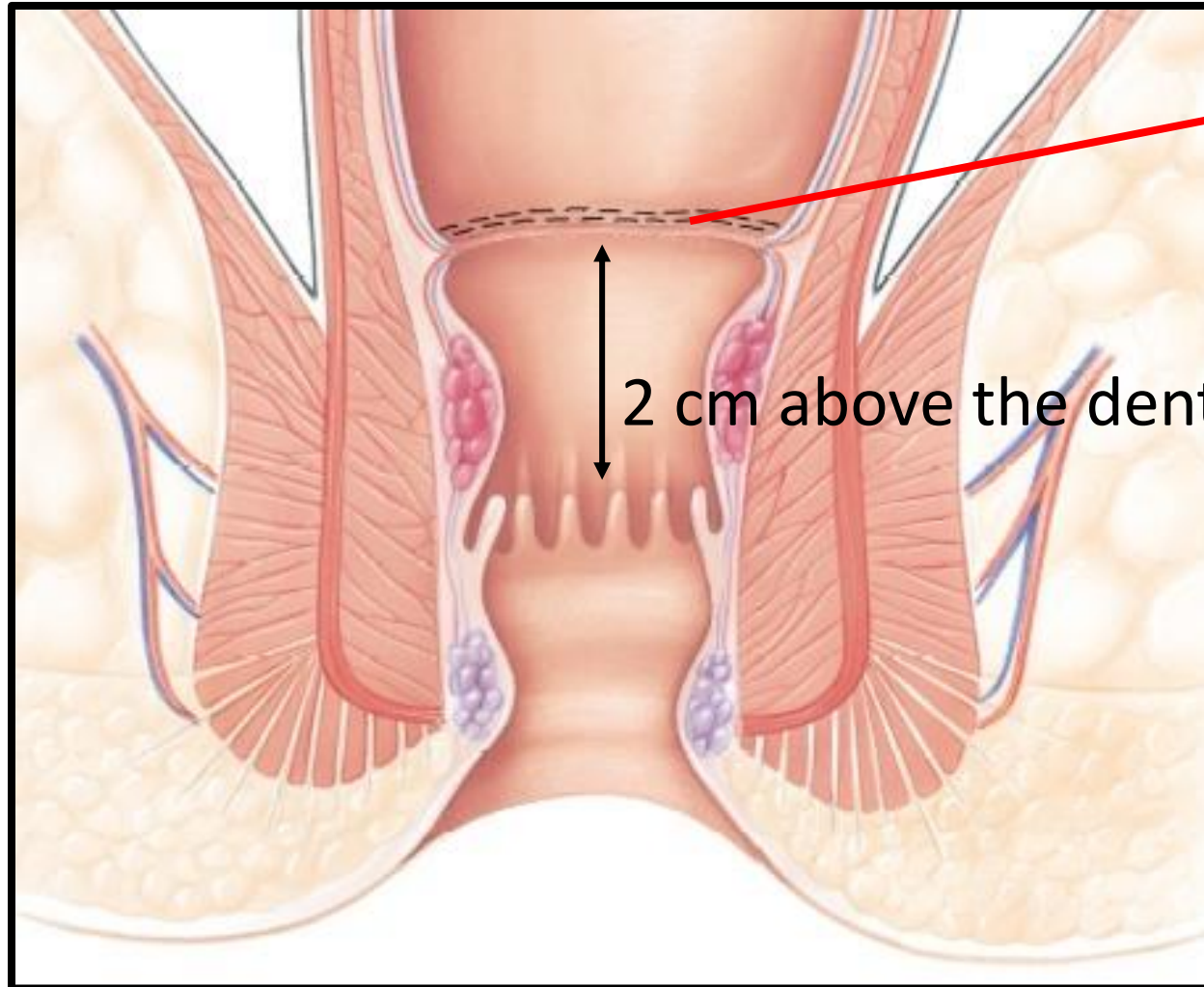


# Stapler for Longo operation






# Stapled Hemorrhoidopexy



Stapler line

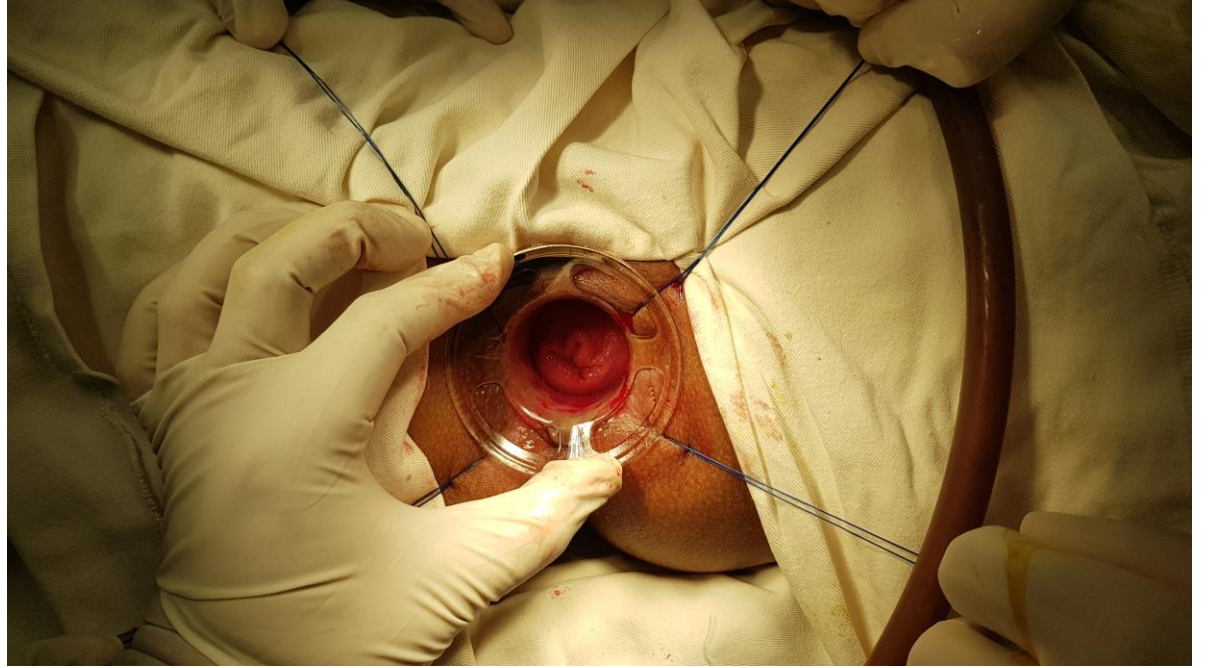
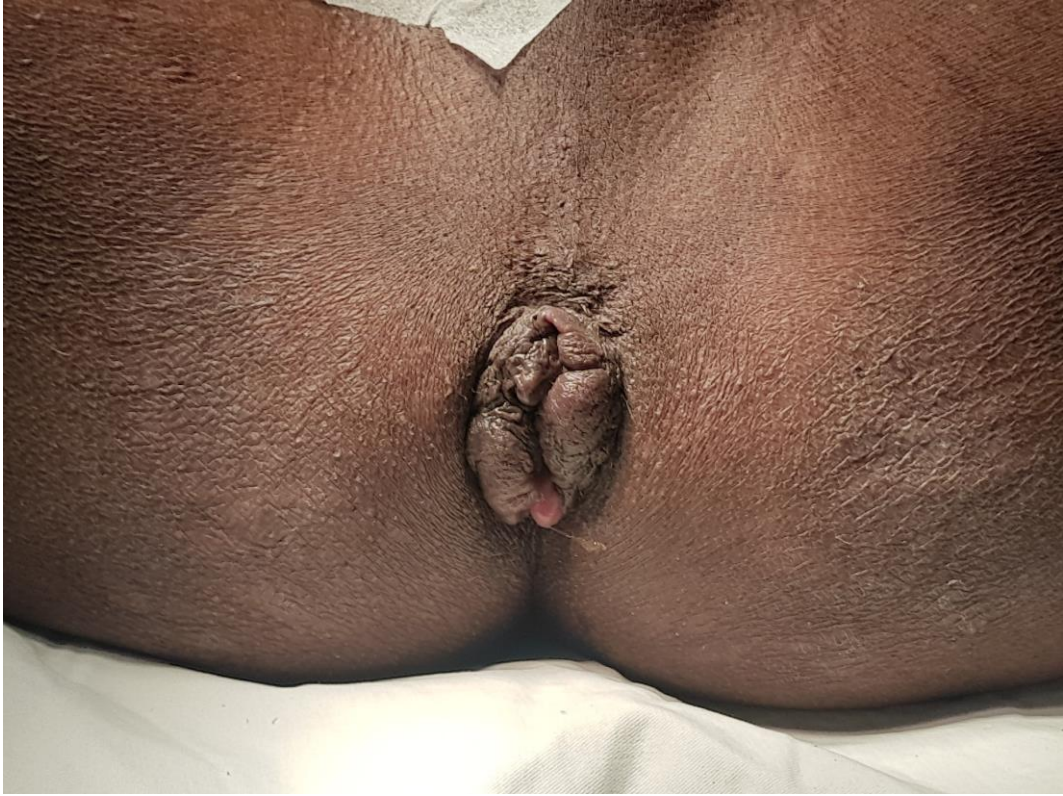2 cm above the dentate line

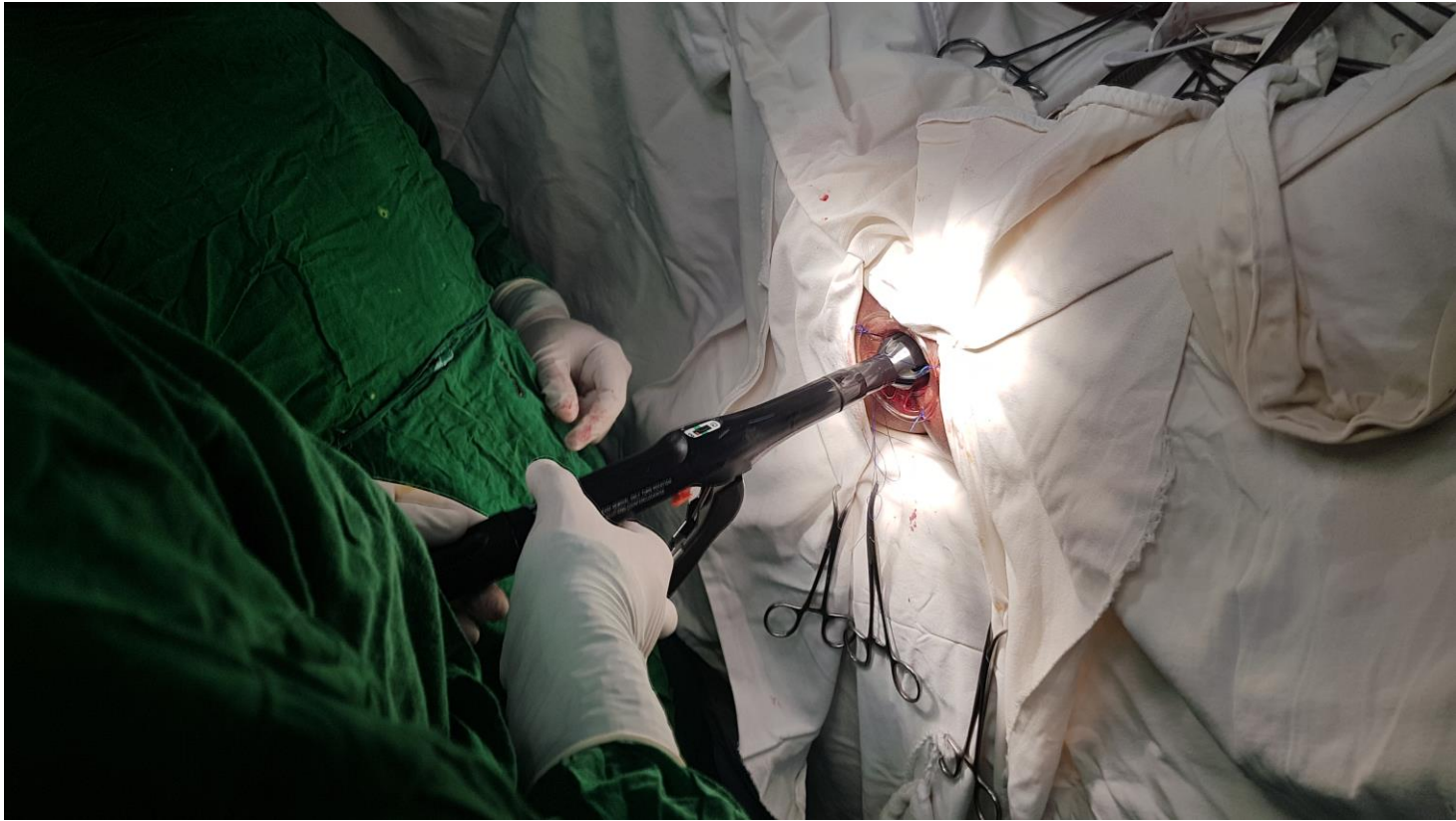

In 1998, Italian surgeon Antonio Longo described the Stapled hemorrhoidopexy



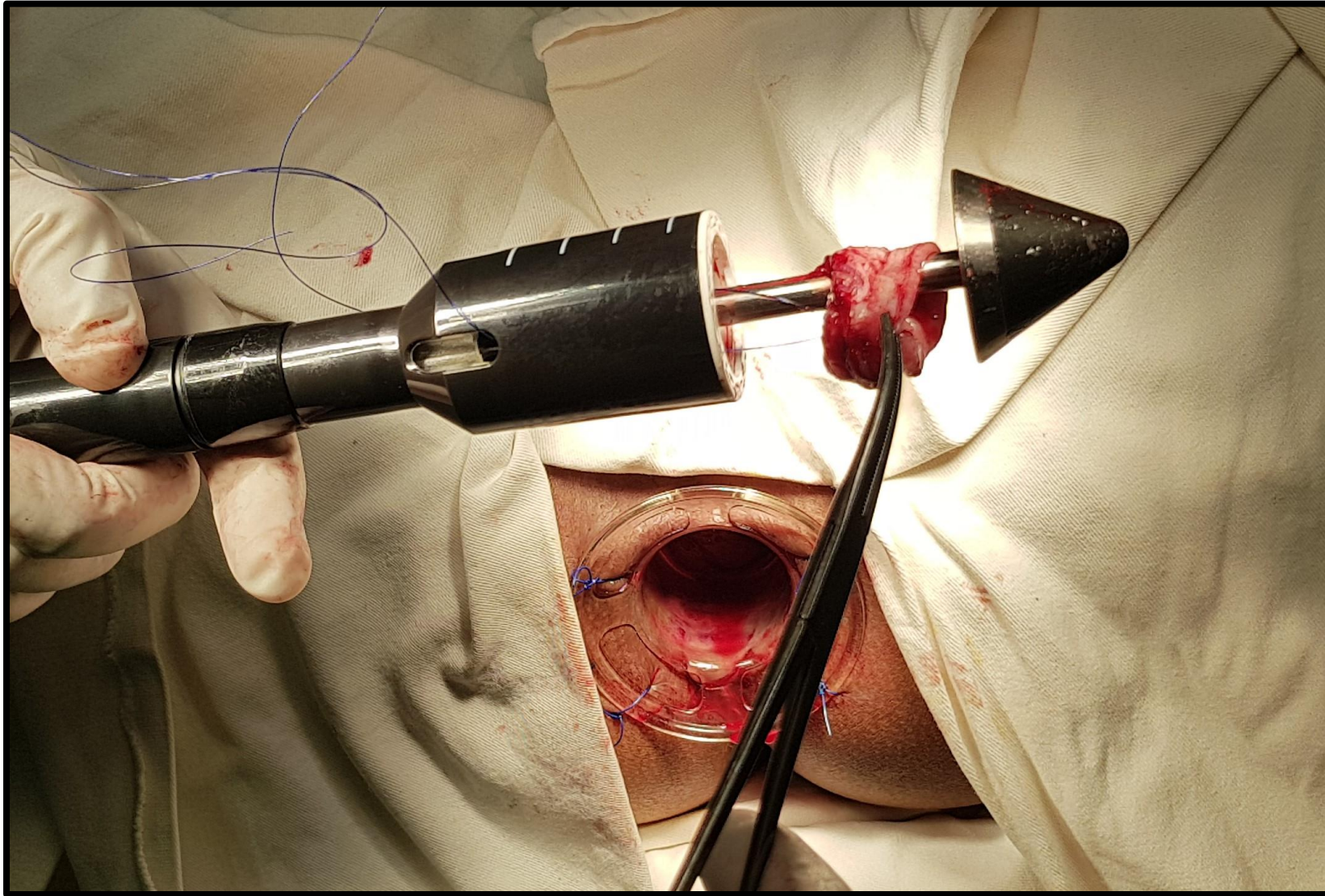






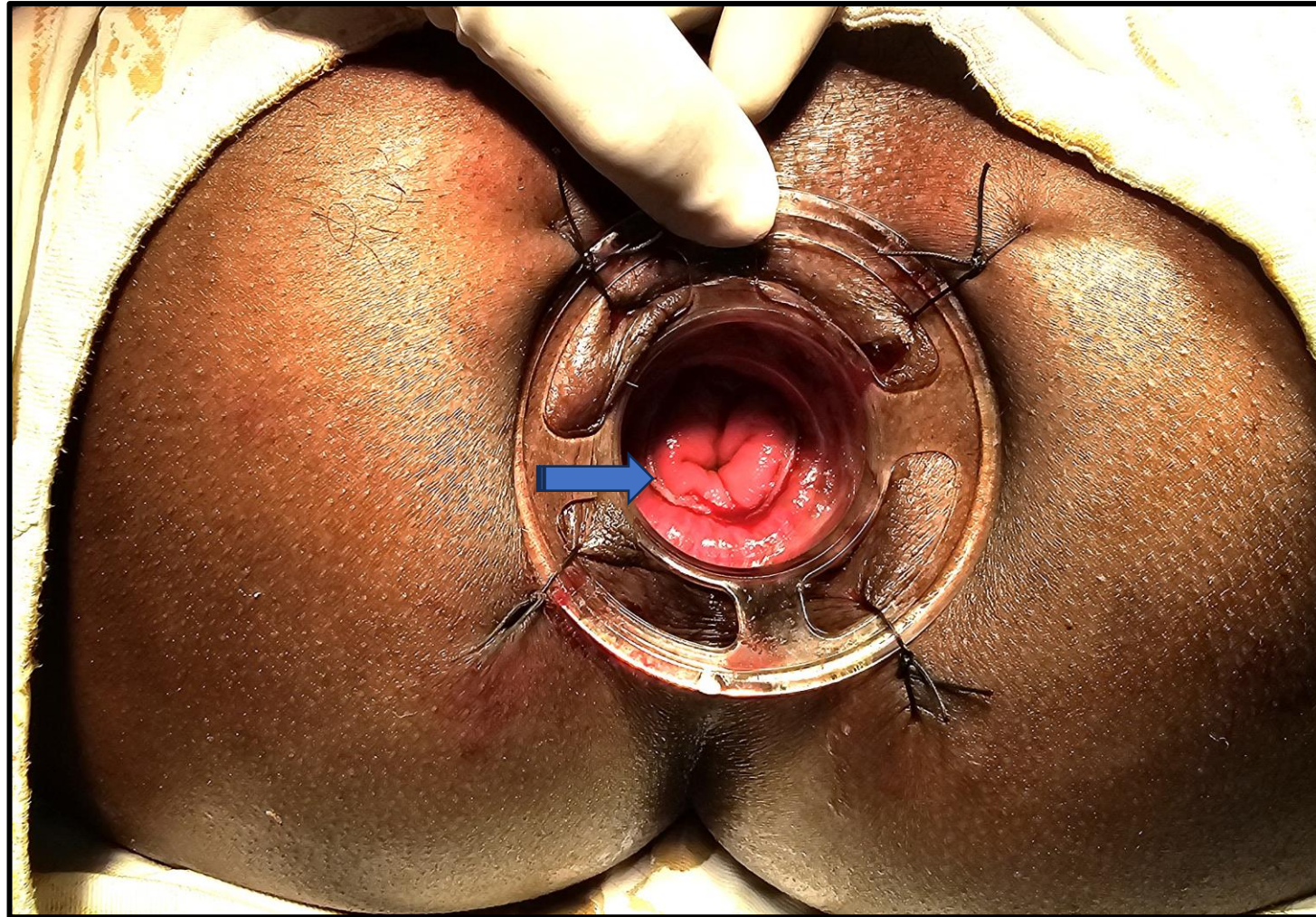


# Stapler dough nut



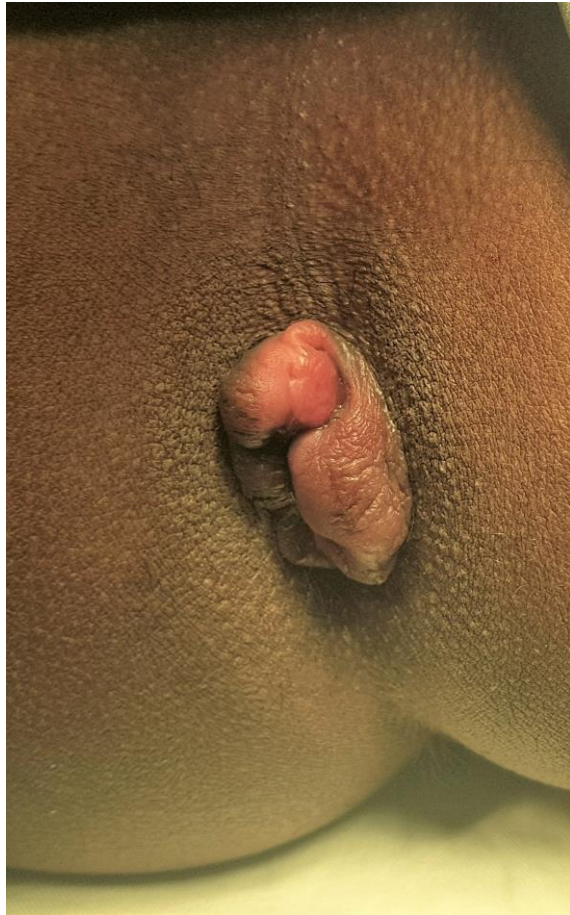


# Visible stapler line

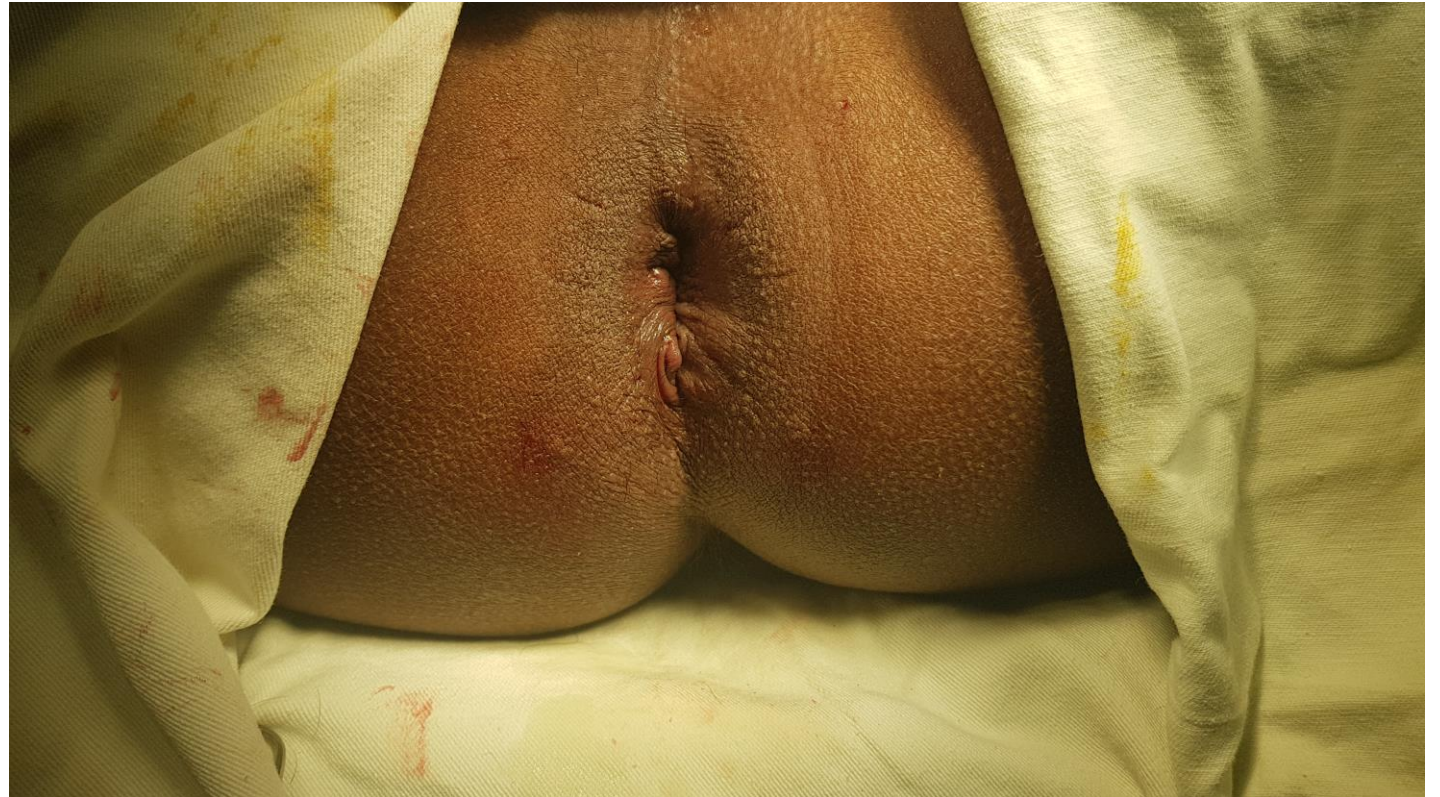



Before Surgery

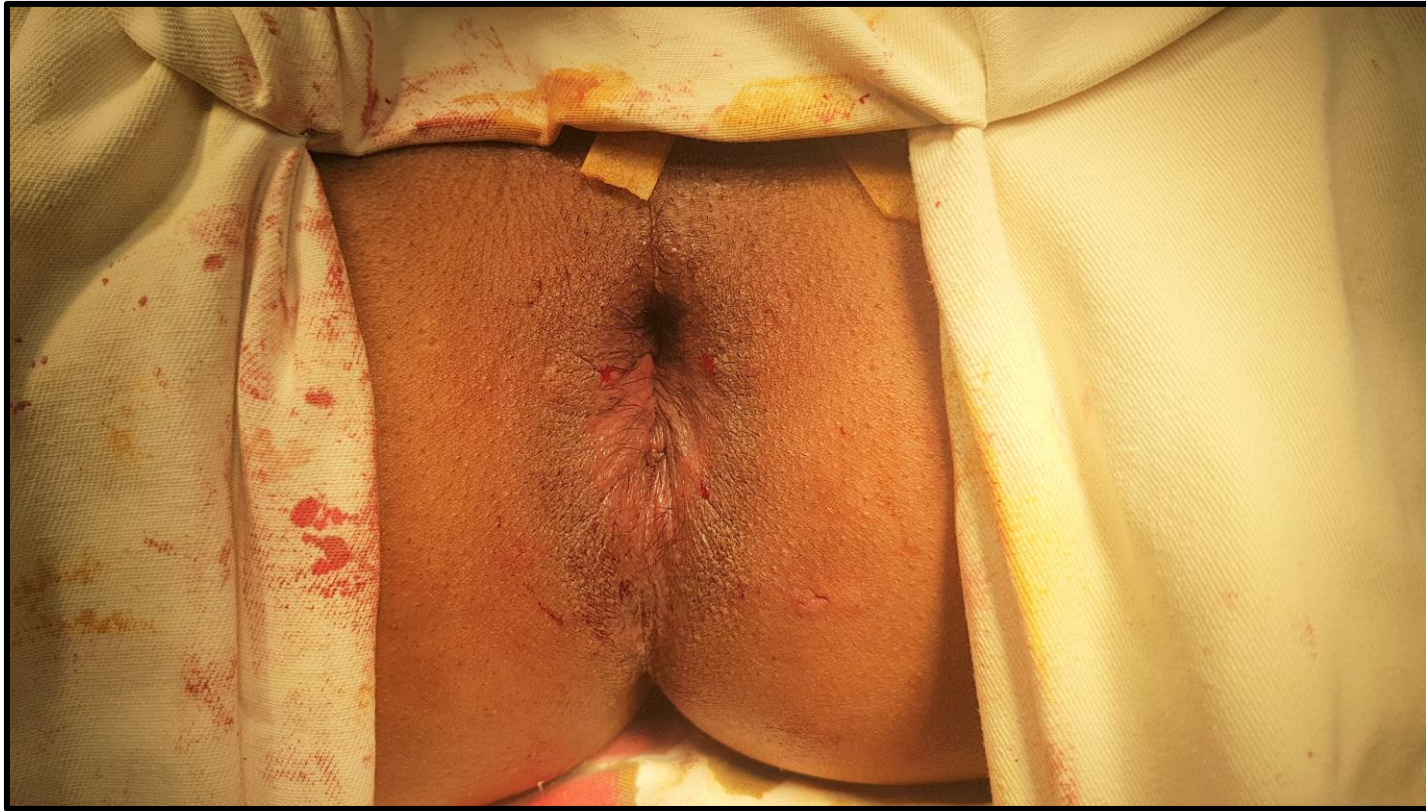

After Surgery

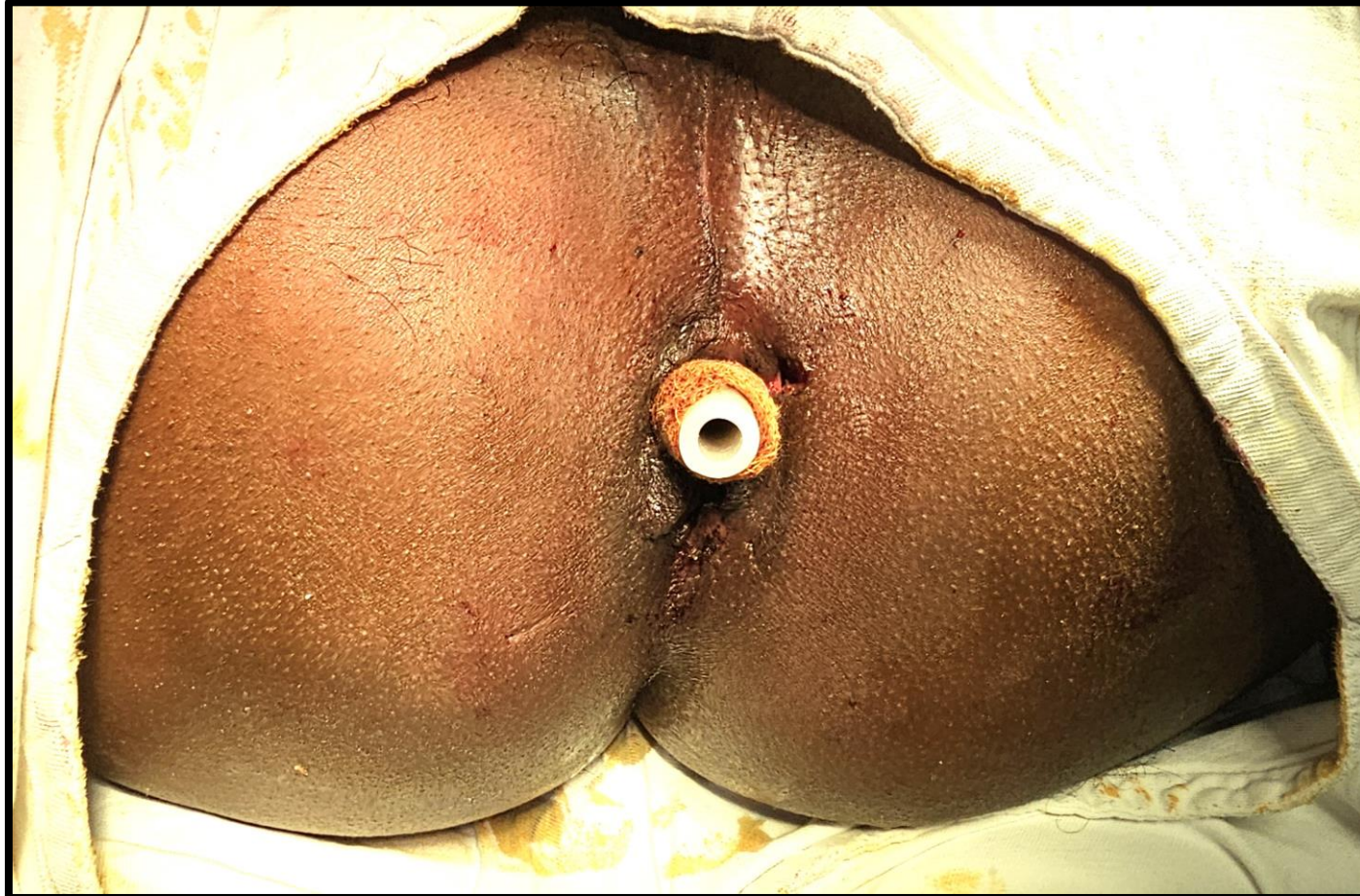



# Final picture



Flatus tube inserted

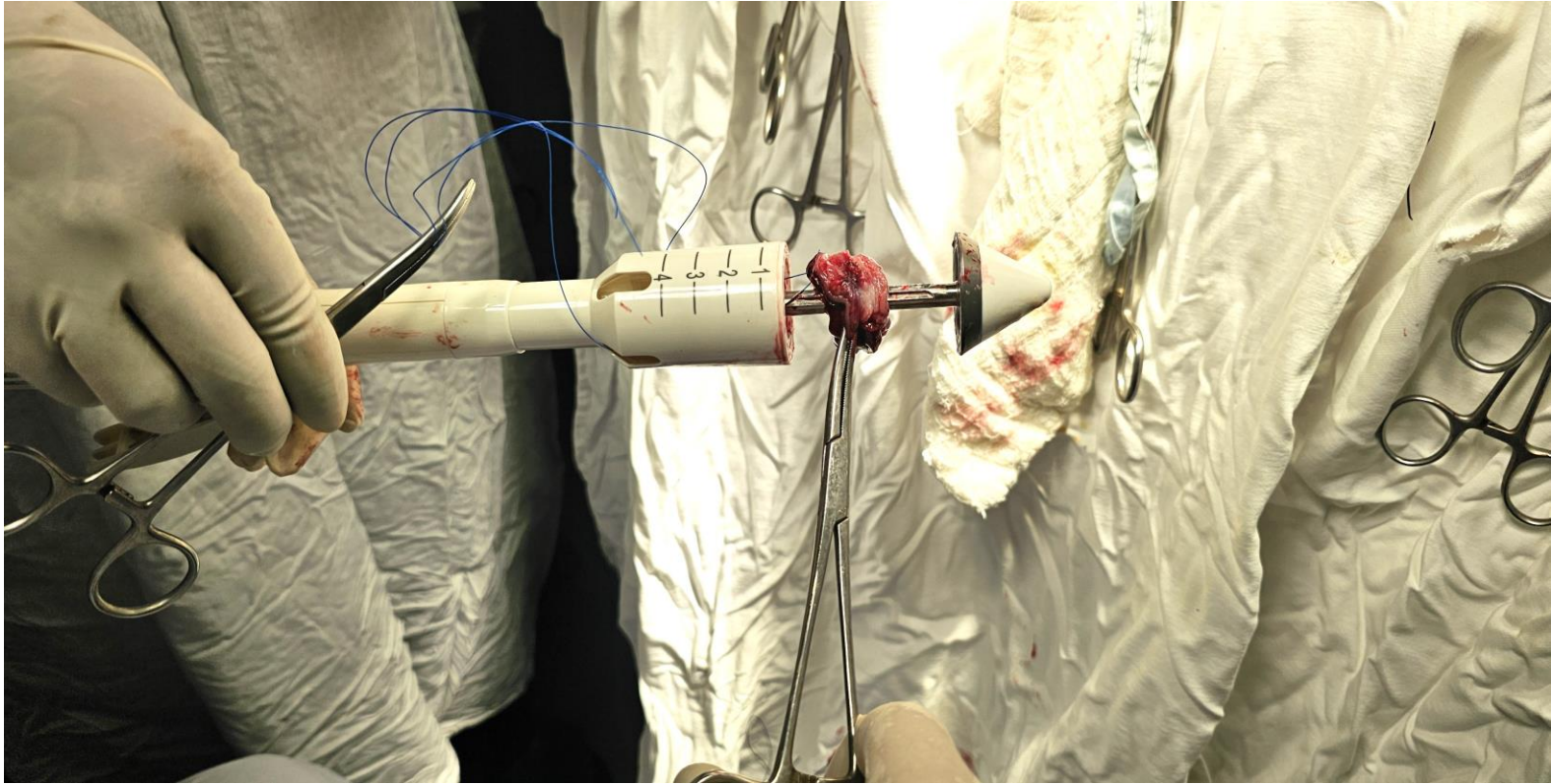
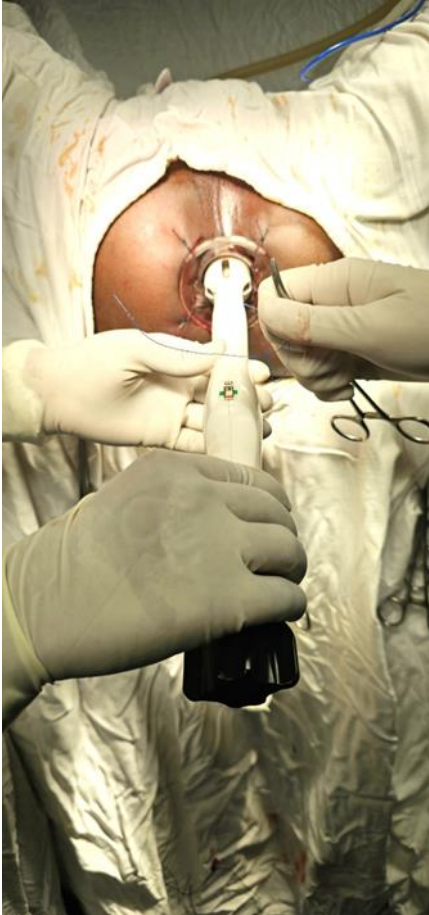




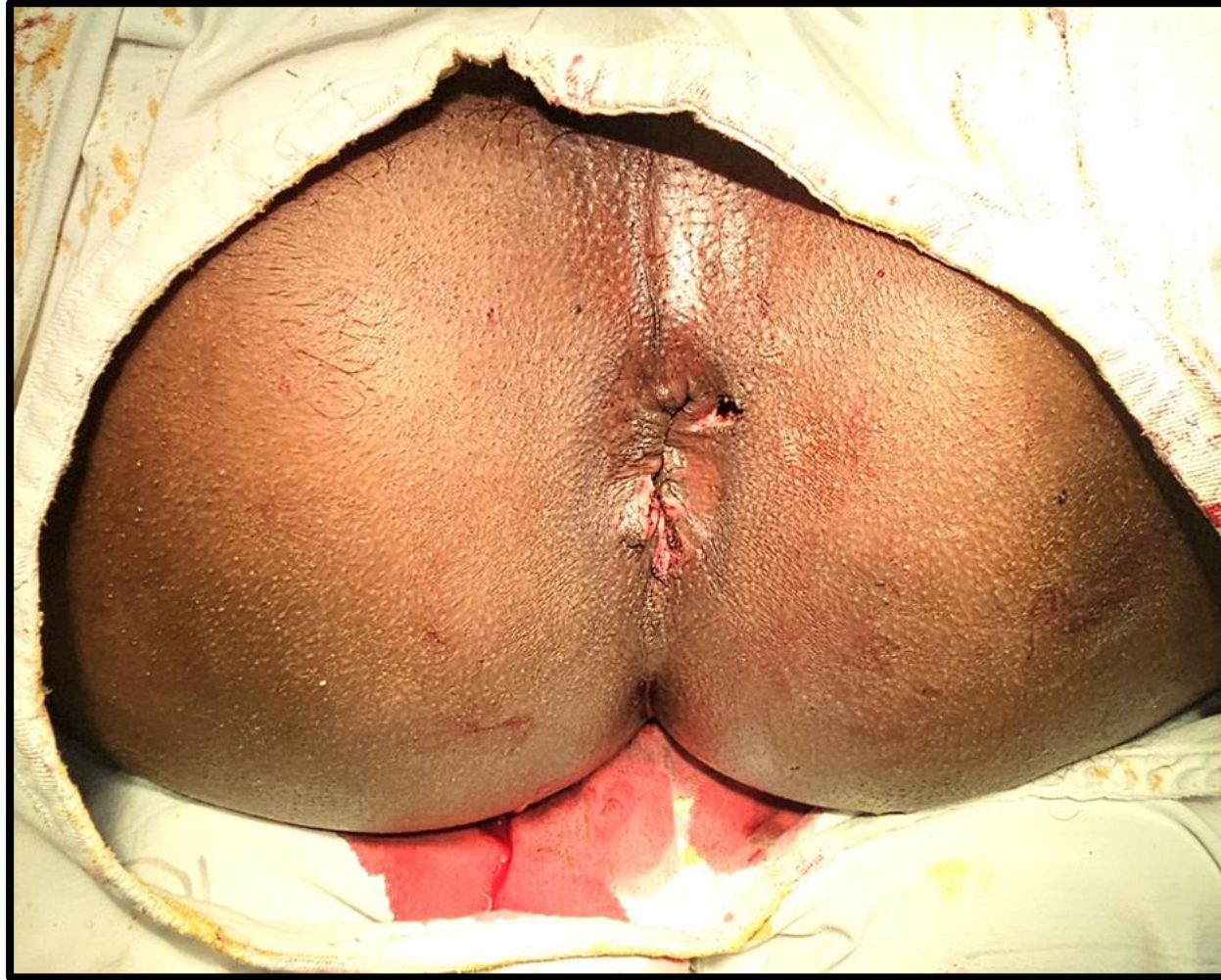


# Stapler gun 36 mm size

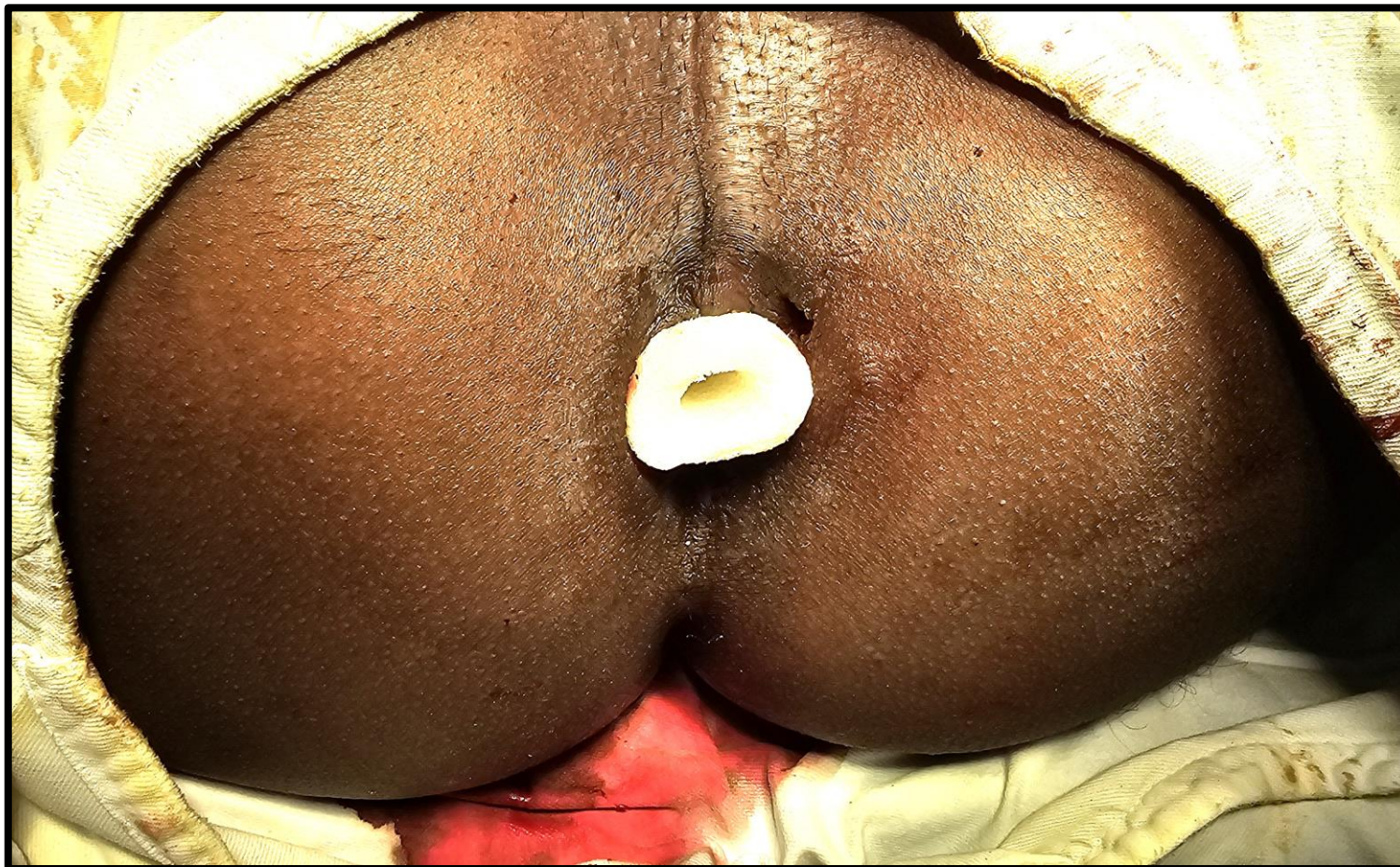


# Post operative picture





Hemo-sponge inserted



# Advantage of Longo operation

- No bleeding
- No open wound
- No pain
- No infection
- Early return to work
- Almost no recurrence
- Correction of mild to moderate degree ODS.
- Patient's satisfaction is high.

# Study period from Dec 2013 to Dec 2023 in 3 hospitals(JIMC<Imperial Hospital CTG<AWMC)

- Total 1861 patients
- Age-12 years to 91 years
- Recurrence-3(0.16%)
- Anal stenosis-5(0.26%)
- Re-operation - Needed for 3(0.16%) patients with Milligan Morgan open technique.



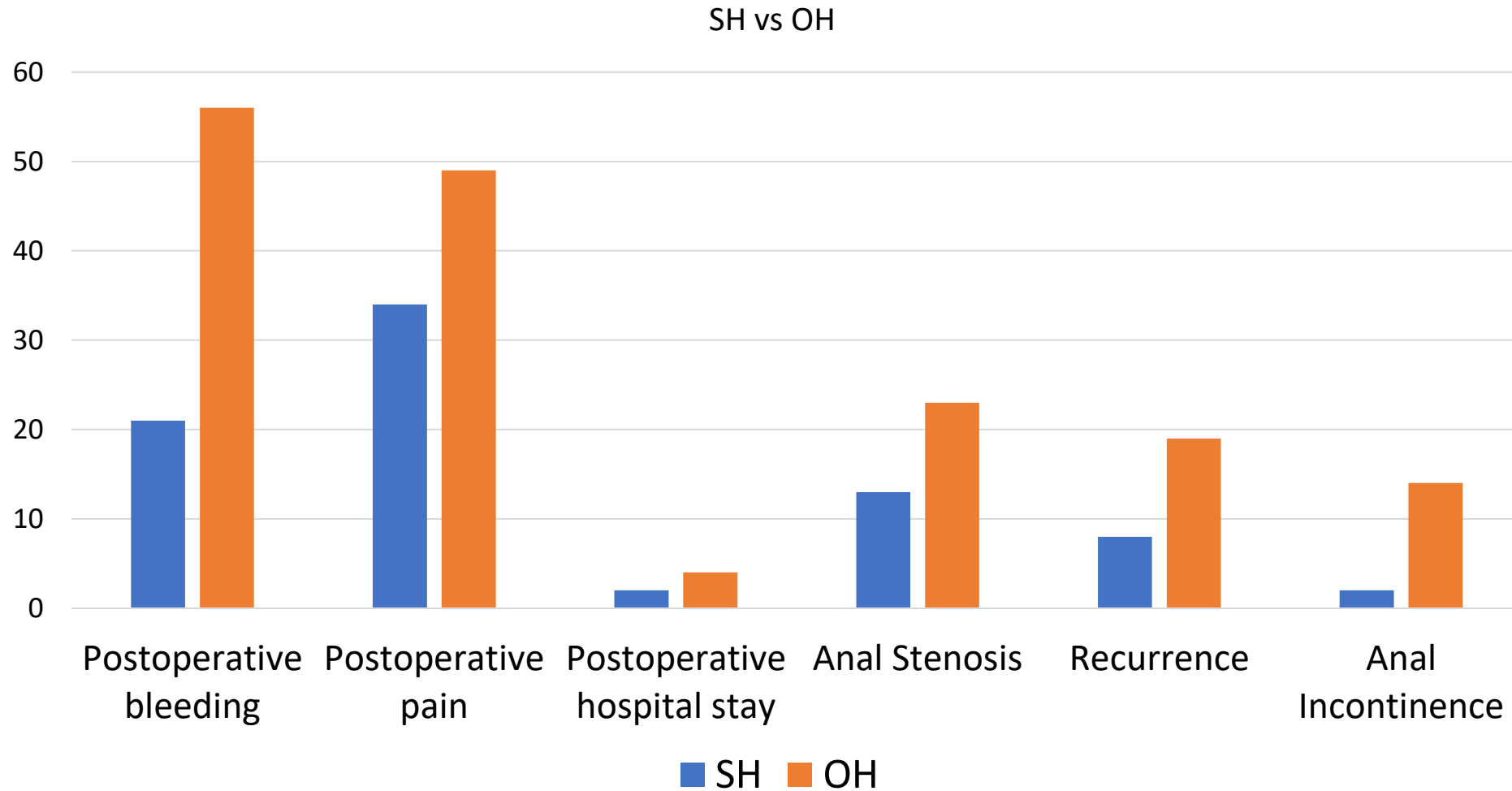
# Study in BSMMU(Colorectal Department) From 2012-2022

- Total patients- 3476
- Open hemorrhoidectomy(OH) done for—1033.
- Stapped hemorrhoidopexy(SH) done for- 2443.
- Follow up done: After 2 weeks
  - After 1 month
  - After 3 months

# SH vs OH

<b>Evaluating points</b>	<b>Stapled hemorrhoidopexy(SH) - 2443</b>	<b>Open hemorrhoidectomy(OH)- 1033</b>
Postoperative bleeding	21 (0.85%)	56 (5.42%)
Postoperative pain	34 (1.39%)	49 (4.74%)
Postoperative hospital stay	1-2 days	3-4 days
Anal Stenosis	13 (0.53%)	23 (2.22%)
Recurrence	8 (0.32%)	19 (1.83%)
Anal Incontinence	2 (0.08%)	14 (1.35%)

# SH vs OH



**Research Article**

**A Prospective Comparative Study of Stapler Hemorrhoidectomy Vs  
Open Haemorrhoidectomy (Milligan Morgan) in its Outcome and  
Postoperative Complications**

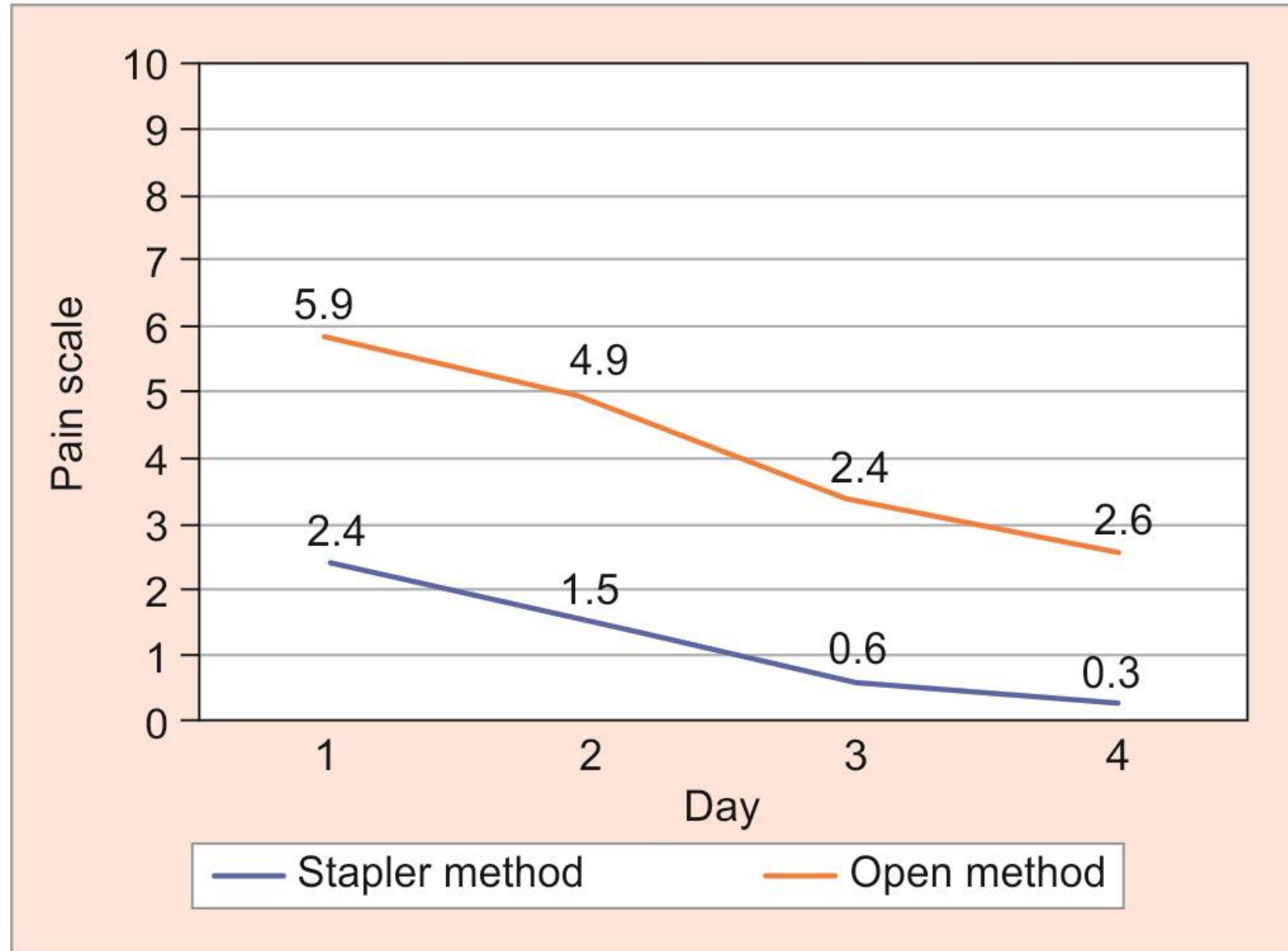
**Dr. Nambula Malyadri<sup>1,\*</sup>, Dr. Veera Jayachandra Allu<sup>2</sup>**

# SH vs OH

	Stapler haemorrhoidopexy (N=40)	Open hemorrhoidectomy (N=40)	P Value
Post-operative bleeding(ml) Median (IQR)	2(1 to 2)	12 (10 to14)	<001*
Post-operative pain- <b>VAS score</b> Median (IQR)	3(3 to 4)	5 (5 to 6)	<0001*
Post-operative Hospital stay in days Median (IQR)	1(1 to 1)	3 (3 to 3)	<0001*
Recurrence	2 (5%)	1(2.5%)	0.556
Incontinence	0 (0%)	3 (7.5%)	**
Anal stenosis	0 (0%)	2 (5%)	**



# Pain score SH vs OH



# Conclusion

- Since the introduction of Stapled hemorrhoidopexy, the procedure has rapidly gained its place throughout the world.
- The technique is effective, and its immediate tolerance has been clearly demonstrated comparison to open hemorrhoidectomy.
- Considering the widespread acceptance of Stapled hemorrhoidopexy, it is time to acknowledge it as the 'Gold Standard Treatment for Hemorrhoid'.

A photograph of a rustic 'Thank you!' tag. The tag is a rectangular piece of light brown, textured cardboard with a hole on the left side, through which a black string is threaded. The words 'Thank you!' are written in a black, cursive script. To the right of the tag is a single white daisy with a bright yellow center. In the background, two more daisies are visible, slightly out of focus. The entire scene is set on a light-colored, textured wooden surface.

Thank  
you!